



Cesarean Sectional as a Treatment of Dystocia Caused by Uterine Torsion in Mehsana Buffalo

Sachin Kalaswa ^{a*}, Ravindra Jadav ^a, Janak Panchal ^a, Vipul Solanki ^a, Keshav ^b, H. C. Nakhashi ^a and B. N. Suthar ^a

^a Department of Veterinary Gynaecology and Obstetrics, College of Veterinary Science and Animal Husbandry, Sardarkrushinagar, Dantiwada, Kamdhenu University, Gujarat, India.

^b Department of Animal Reproduction, Gynaecology and Obstetrics, Assam Agricultural University, Khanapara, Guwahati, Assam, India.

Authors' contributions

This work was carried out in collaboration among all authors. All authors read and approved the final manuscript.

Article Information

DOI: 10.9734/ARRB/2024/v39i52076

Open Peer Review History:

This journal follows the Advanced Open Peer Review policy. Identity of the Reviewers, Editor(s) and additional Reviewers, peer review comments, different versions of the manuscript, comments of the editors, etc are available here:

<https://www.sdiarticle5.com/review-history/115239>

Original Research Article

Received: 07/02/2024

Accepted: 10/04/2024

Published: 15/04/2024

ABSTRACT

A case of dystocia due to post-cervical right side uterine torsion with the history of colic and straining since (days) in a pluriparous Mehsana buffalo was presented at the clinics of Veterinary Gynaecology and Obstetrics of Veterinary College, Sardarkrushinagar, Dantiwada, Gujarat, India. Maternal dystocia due to of uterine torsion was diagnosed by history, a clinical sign, per rectal and per vaginal examinations. At first we used modified Schaffer's method for management of uterine torsion in buffalo. After the three rolls torsion was detorted successfully, but due to insufficient dilated cervix the fetus could not be delivered. Further, the buffalo was treated therapeutically using intravenous administration of 10ml-Dexamethasone[®], 75IU-Oxytocin[®], 1litre-Normal saline, 1litre-Ringer lactate, 100ml-Calcium borogluconate and 10ml-Valethamate bromide (Epidosin[®]) was given

*Corresponding author: E-mail: s.m.kalaswa23@gmail.com;

intramuscularly for treating incomplete cervical dilation(ICD). However, the buffalo could not responded to treatment, therefore finally the caesarean section was performed and a dead male fetus was delivered. Buffalo was post-medicated with various fluids, analgesic, antibiotic and antihistamine parentally apart from intra-uterine pessaries which resulted to recovery of affected Mehsana buffalo within some days.

Keywords: Uterine torsion; buffalo; detorsion; caesarean section.

1. INTRODUCTION

There are several conditions following successful conception which adversely, affect the normal progression of pregnancy and parturition. Among the reproductive disorders, uterine torsion is a major condition affecting buffaloes during late pregnancy [1]. The uterine torsion is a maternal cause of dystocia occurring commonly at the time of parturition and characterized by rotation of uterine horn on its longitudinal axis. It occurs as a complication of late first stage or early second stage labor due to fetal weight and violent movements of fetus during parturition [2,3]. The rotational displacement of entire length of gravid uterine horn with fetus and membranes either clockwise or anticlockwise, compressing blood vessels, causing hemorrhage and seepage of blood into allantoic cavity resulting in fetal death in utero [4]. Higher degree of torsion persisting for prolonged duration increase severity of pathological changes of uterus and cervix which in turn influence calf and dam survival rate if corrective measures are not taken. Under field conditions, torsion needs to be diagnosed by qualified Veterinarian and required corrective measures and immediate surgical intervention if needed to save life of dam.

2. MATERIALS AND METHODS

2.1 Case History and Clinical Observation

A four years old Mehsana buffalo with 1st parity was presented to the clinics of Veterinary Gynaecology and Obstetrics of Veterinary College, Sardarkrushinagar, Dantiwada, Gujarat, India with the history of completion of gestation period, water bag was not ruptured, restlessness and tenesmus since last four days, without any progress in parturition. Physiological parameters recorded were in the normal clinical range; temperature (102.7^oF), respiration rate (20/minute) and while heart rate was slightly elevated (92/minute). Clinical symptoms include the buffalo was partial anorexic since four days, non progressive labor, colic signs, depression,

restlessness arched back and slightly dehydrated with standing condition. The buffalo was frequently getting up and down showing extreme abdominal pain and previously, the case treated by local field veterinarian and they failed to detort after one rotation.

Clinical observation revealed that the normal pelvis, pelvic ligaments were not relaxed, valva and valval lips were slight oedematous with mild twist at right side, conjunctival (Fig.1) and vaginal (Fig. 2) mucous membranes membrane were slightly congested, mammary glands fully engorged with milk (Fig. 3) and vaginal discharged was not observed.

“On per-vaginal examination revealed that the uterine fluid discharges was not observed, vagina was relaxed, severe twisted vaginal fold was palpated going toward right lateral side side and the external os-cervix could not be palpated or unable to palpate the cervix. On per-rectal examination revealed that the broad ligament of left side is stretched (extending) toward the right side (right side broad ligament sinking beneath the uterus), uterine surface was tense with thick walled, fremitus was absent, foetus was not palpated. Further, complete two uterine fold were palpated and the arrangement of broad ligaments with the spiral twist in the uterus just post-caudal to the cervix indicated more than 270^o right-sided uterine torsion. Based on the history, a clinical sings, per-vaginal and per-rectal examination the case was diagnosed as post-cervical right side uterine torsion of about 270^o rotation” [5].

2.2 Obstetrical, Therapeutic and Surgical Management

Rolling the animal by using modified Schaffer's method: Buffalo was casted on its right side lateral recumbence in the direction of torsion and the front and hind legs were tied secured separately (Fig-4 and Fig-5) and uterine torsion was corrected using modified Schaffer's method by rolling the animal in the direction of torsion. “Dam rotated to the same degree and

direction to which the uterus has rotated, keeping the fetus fixed by fixing uterus with a wooden plank (length: 10 feet, width: 1 feet and thickness: 1 inch)" [6]. The wooden plank was placed on the upper paralumbar fossa of dam in an inclined manner with lower end on ground (Fig. 6). "The animal was rolled over on to its back, the front and hind legs were pulled up and over the recumbent dam. While rolling, wooden plank was anchored by 1-2 medium weight assistants who stood still upon the lower end of wooden plank and another assistant moved on the plank. An additional assistant modulated the pressure on the plank by pressing the upper end of plank. After each roll, effectiveness of roll was judged by transvaginal examination" [5]. In this case three rotation were given in clockwise (Fig. 7, right side) direction by using Modified Schaffer's method and improvement was observed in form of disappearance of the vaginal spirals or rectal pouch could be immediately palpated and a gush of discharge appeared through the vagina. On proper lubrication (liquid paraffin) with antiseptic (1% potassium permanganate lotion) per vaginal examination revealed that the torsion was completely relieved, vaginal bloody discharge was observed, cervix was firm and about 4 fingers

dilation observed but foetus or any movement of foetus was not palpable. The buffalo was treated for incomplete cervical dilation with (Fig. 8) with intravenous administration of 10ml-Dexamethasone®, 75IU-Oxytocin®, 1litre-Normal saline, 1litre-Ringer lactate and 100ml-Calcium borogluconate, whereas 10ml-Valethamate bromide (Epidosin®) was given intramuscularly. After three hours of treatment per-vaginal examination revealed that the cervix was not completely dilated and the improvement chances were less. So finally caesarean section was performed under local infiltration analgesia using 2% lignocaine hydrochloride.

2.3 Surgical Management

Pre-operative intravenous fluids (DNS 5%) @ 10ml/kg and Dexamethasone @ 1mg/kg as I/V given to correct to stabilize the animal. Enrofloxacin @ 5mg/kg was injected I/M as a prophylactic and post operative antibiotic. Sedation was achieved with Xylazine hydrochloride @ 0.05 mg/kg b.wt. IV and to reduce salivary secretions and bradycardia, buffalo was premedicated with Atropine sulphate (0.4mg/kg) I/M. Animal was casted in right lateral recumbency while fore and hind limbs are

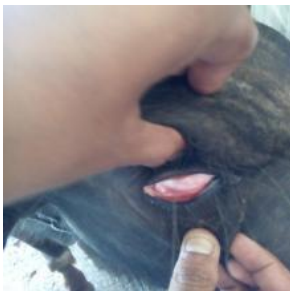

Fig.1 & 2. Conjunctival and Vaginal mucous membrane were slightly congested

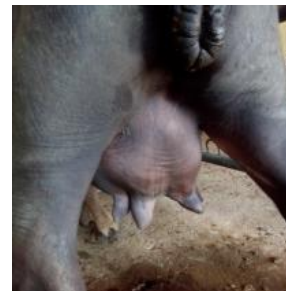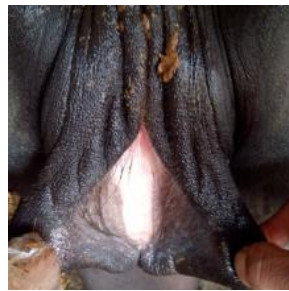


Fig. 3. Mammary glands fully engorged with milk



Fig. 4. Restraining the buffalo by holding fore limbs and hind limbs of buffalo



Fig. 5. Restraining the buffalo in right lateral recumbency



Fig. 6. Placing the plank over the abdomen



Fig. 7. Rotation of animal in clock wise direction



Fig. 8. Buffalo pre-medicated treatment

secured tied separately and site was prepared for aseptic surgery. Local analgesia was induced by infiltration with 2% Lidocaine hydrochloride. The left oblique ventrolateral or left lateral and parallel to milk vein the incisions was made and with precaution oblique abdominal muscle was incised (Fig. 9). Further, peritoneum incised & opened (Fig. 10), the uterus was exteriorized. Later, the incision was made on the greater curvature of uterus avoiding cotyledons (Fig.11). The dead male fetus was removed along with, placenta and four Furea bolus (control the uterine infection- Allopathic remedies, India) were kept inside uterus. Uterine incision was closed by cushioning followed by double row of lembert pattern sutures using chronic catgut no.1#0 (Fig.12), The remaining peritoneum, muscles and sub-cutis layers were closed by continuous lock-stich pattern using chronic catgut no.2#0; then lastly skin layer was closed by horizontal mattress sutures pattern using cotton

thread a non-absorbable sutures material (Fig.13). The buffalo got up by herself within 15 minutes after the dead emphysematous large size male calf was delivered. Then the buffalo was post-medicated (Fig.7) with intramuscularly administration of 10ml-Chlorpheniramine maleate (Antihistamines), 10ml-Vitamin B-complex Injection, Melonex® (Meloxicam-Intas, India) @ 0.5mg/kg. b.wt. IM OD and Quintas® (Enrofloxacin-Intas, India) @ 5mg/kg. B.wt. IM OD; whereas 1litre Ringer lactate, 1litre Dextrose normal saline (5%DNS) were given intravenously. Also gave, the Liquid Exapar® (Indigenous herbal uterine cleanser and restorative-Natural Remedies, India) @ 50 ml twice PO and liquid Gluca-boost (To maintain the energy/glucose-Natural Remedies, India) @ 200ml once PO. Advise to continue antibiotic, analgesic and antihistamine intramuscularly for 7 days.

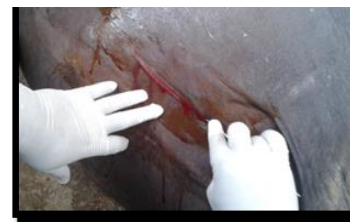


Fig. 9. Aseptic precaution with oblique abdominal incision extending from point of stifle towards umbilicus above 5 cm parallel to milk vein on left side

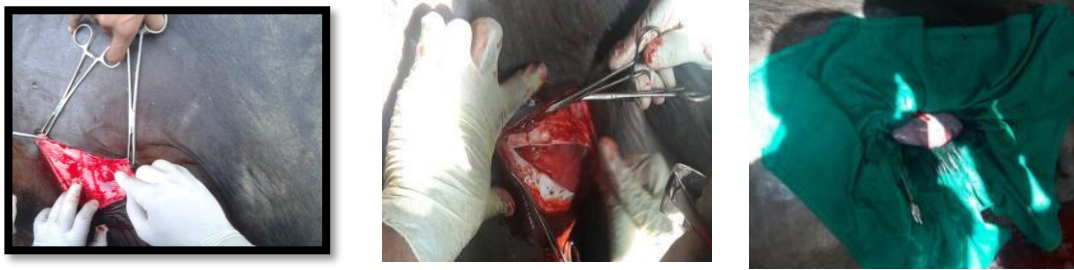

Fig. 10. skin, muscle, peritoneum and uterus were opened by incised in longitudinal fashion

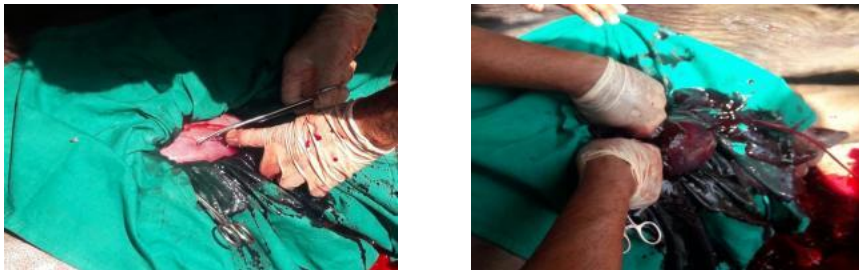

Fig. 11. The exteoration of uterus, uterine amniotic cavity and its wall was incised in longitudinal fashion at greater curvature avoiding cotyledons

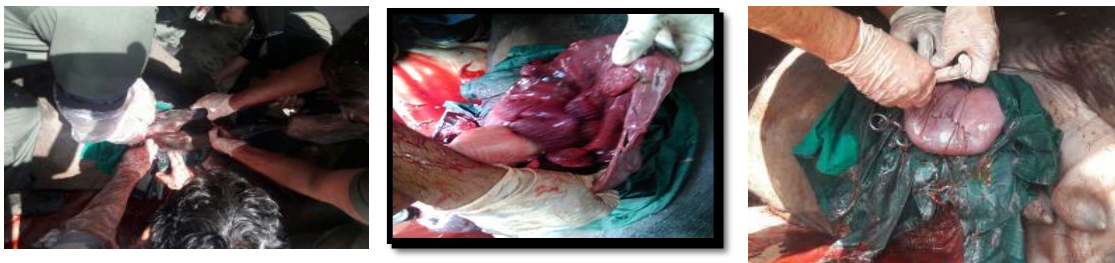

Fig. 12. The dead male fetus was extracted, fluids were drained, placenta removed manually and four furea bolus kept inside uterus and uterine incision was closed by cushioning followed by double row of lembert pattern sutures using chronic catgut no.1#0 .

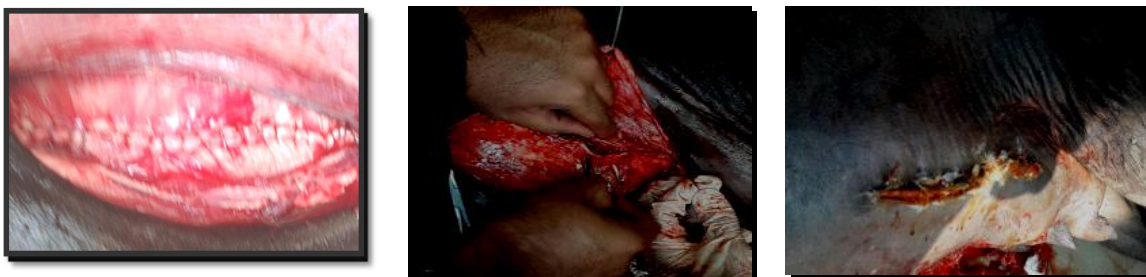

Fig. 13. The remaining peritoneum, muscles and sub-cutis layers were closed by continuous lock-stitch pattern sutures using chronic catgut no.2#0; then lastly skin layer was closed by horizontal mattress pattern sutures using cotton thread non absorbable sutures material.

3. RESULTS AND DISCUSSIONS

Information of the patient was taken telephonically every alternate day following discharge from hospital. The buffalo was found active and alert resuming normal appetite within

a seven days post treatment. Eventually, the buffalo recovered uneventfully. In this complicated unresponsive case of uterine torsion, where standard physical obstetrical procedures and medicinal therapy are unsuccessful, then cesarean section appears to

be most ideal intervention to save dam (Fig.14), if performed within time. In this case post-cervical right side 270° torsion with incomplete dilated cervix were observed, this may be due to rumen occupying left side of abdominal cavity. All above observations are in agreement with authors (Verma et al., [7], Krishnamurthy et al., [8] and Purohit et al., [9] who reported delivery of dead emphysematous male fetus by cesarean section at almost similar stage of gestation with dystocia due to uterine torsion. Sharma et al., [5] also reported dystocia due to uterine torsion with degree of torsion 180-270° and above 270° with post cervical torsion as most common cause. Gurnam and Sunesh, [10] have reported that the further myometrial contractions, changes in intra-uterine pressure, changes in fetal blood flow and inability of relaxed and unstable uterus to restrict movement of upper portion of fetus as contributory factors for occurrence of uterine torsion. Further, history and clinical findings suggest that the sudden fall, sudden push from other animal and bumpy movements during fast walking or wandering here and there, habit of wallowing, sudden slipping from banks of irrigation canals while grazing are contributory causes for uterine torsion. In addition, while lying down, buffalo go down on fore legs first and while getting up, hindquarters are relived first, thus each time, pregnant uterus is temporarily suspended in abdominal cavity and is prone to torsion, these all observations were corroborated with present case report. Whereas, Verma et al., [7] and Purohit et al., [9] also reported the surgical site i.e., left oblique ventrolateral or left lateral and parallel to milk vein, considered as a better one due to adequate exposure of operation site, easy to approach the uterus, fewer chances of herniation, less contamination, smaller incision, due to this reason, we also selected the same site for surgical procedures.

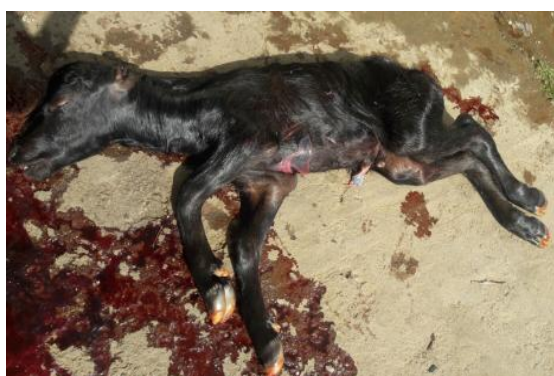

Fig-14: Delivered dead large size male fetus

5. CONCLUSION

In this case of maternal dystocia due to uterine torsion in Mehsana buffalo, sound diagnosis, timely interventions for detorsion by adopting modified Schaffer's detorsion method could be a better managerial practice. However, in delayed cases successful caesarean section could save the life of the buffalo when uterine torsion case complicated with incomplete cervical dilatation (ICD).

COMPETING INTERESTS

Authors have declared that no competing interests exist.

REFERENCES

1. Gupta RC, Sharma AK, Verma SK, Khar SK, Datt SC. Studies on various reproductive disorders in buffaloes (*Bubalus bubalis*). A clinical review. *Philippine Journal of Veterinary Medicine*. 1981;20: 133-144.
2. Sheehan KH. Caesarean section for dystocia: A comparison of practices in two countries. *The Lancet*. 1987;329(8532): 548-51.
3. Arthur GH, Noakes DE, Parkinson TJ, England GCW. *Veterinary Reproduction and Obstetrics* 8th ed. WB Saunders Company Ltd. London. 2001;233.
4. Purohit GN, Barolia Y, Shekher C, Kumar P. Maternal Dystocia in cows and buffaloes: A review. *Open Journal of Animal Science*. 2011;1:41-53.
5. Sharma SP, Agarwal K.BP, Singh OP. Torsion of gravid uterus and laprohysterectomy in bovine--A report on 72 clinical cases. *Indian Veterinary Journal*. 1995;72:1180.
6. Ghuman SPS. Uterine torsion in bovines: a review. *Indian Journal of Animal Science*. 2010;80: 289-05.
7. Verma SK, Manohar M, Tyagi RPS. Caesarean section in bovines: A clinical study. *Indian Veterinary Journal*. 1974;51: 471-79.
8. Krishnamurthy K, Prasad V, Radhakrishna Murthy P. Clinical observations on uterine torsion in buffaloes. *Indian Veterinary Journal*. 1999;76:643-45.
9. Purohit GN, Gaur M, Kumar A, Shekher C, Swati R. Perspectives of cesarian section in buffaloes. *Asian Pacific Journal of Reproduction*. 2013;12:229-235.

10. Gurnam SP, Sunesh K. Torsion of Uterus in Pregnant Buffaloes: Early Intervention is Really Important. Buffaloepedia. Accessed through internet. 2011;3.

© Copyright (2024): Author(s). The licensee is the journal publisher. This is an Open Access article distributed under the terms of the Creative Commons Attribution License (<http://creativecommons.org/licenses/by/4.0>), which permits unrestricted use, distribution, and reproduction in any medium, provided the original work is properly cited.

Peer-review history:

The peer review history for this paper can be accessed here:

<https://www.sdiarticle5.com/review-history/115239>