



# Immediate and Short-Term Results of Balloon Pulmonary Valvuloplasty from Neonates to Grown Up Children with Critical Pulmonary Stenosis: Experience from a Tertiary Care Centre in Bangladesh

Rezoana Rima <sup>a++\*</sup>, Abu Sayeed Munshi <sup>a#</sup>, Abdul Jabbar <sup>bt</sup>  
and Md. Khalid Ebne Shahid Khan <sup>at</sup>

<sup>a</sup> Department of Paediatric Cardiology, Bangladesh Shishu Hospital and Institute, Dhaka, Bangladesh.

<sup>b</sup> Cardiac Intensive Care Unit, Bangladesh Shishu Hospital and Institute, Dhaka, Bangladesh.

## Authors' contributions

This work was carried out in collaboration among all authors. All authors read and approved the final manuscript.

## Article Information

DOI: 10.9734/AJPR/2023/v13i4297

## Open Peer Review History:

This journal follows the Advanced Open Peer Review policy. Identity of the Reviewers, Editor(s) and additional Reviewers, peer review comments, different versions of the manuscript, comments of the editors, etc are available here: <https://www.sdiarticle5.com/review-history/109352>

Original Research Article

Received: 18/09/2023

Accepted: 23/11/2023

Published: 25/11/2023

## ABSTRACT

**Background:** Although neonates present with critical pulmonary stenosis (PS) it is equally found in grown up children in developing country like Bangladesh. Balloon pulmonary valvuloplasty (BPV) is one of the most common catheter-based intervention. Transcatheter interventions in critical PS

<sup>++</sup> Associate Professor and Head;

<sup>#</sup> Associate Professor;

<sup>†</sup> Registrar;

\*Corresponding author: Email: drrezoana@gmail.com

present unique challenges in Bangladesh due to unavailability of expert centre & hardware, cost of procedure, low weight and delayed diagnosis. Careful technique, proper planning & safety measures reduces the incidence of complications.

**Objective:** The study was undertaken to find out the immediate & mid-term outcome of critically ill neonates, infants, children, adolescent who needed emergency pulmonary valvuloplasty for critical PS.

**Methods:** This retrospective study was conducted in the cardiac centre of Bangladesh Shishu Hospital & Institute between June 2014 to June 2022. Percutaneous balloon pulmonary valvuloplasty done in 54 children having critical stenosis or membranous pulmonary atresia. Clinical parameters, SPO<sub>2</sub>, echocardiographic data, cathlab data & outcome were recorded. Statistical analysis was done by using SPSS version 24.

**Results:** Among these neonates were 6(11.8%), infants between 1 month to one year was 30(58.8%), from 1 year to 5 years 10(19.6%), more than 5 years 5(9.8%). Median weight was 6.5 kg; lowest weight was 1.96 kg. The peak systolic gradient reduced from an average of  $66 \pm 7$  mm Hg to  $16.5 \pm 5$  mm Hg (P value <0.05). No major complication occurred except mild PR, RV dysfunction, transient bradycardia. Two patients died due to sudden cardiac arrest after six hours of procedure. At 1 month follow up 12 patients had mild residual stenosis, 5 had moderate residual pulmonary stenosis and 2 had severe residual pulmonary stenosis. At 6 month follow up four patients had mild residual pulmonary stenosis & one had moderate pulmonary stenosis.

**Conclusion:** Balloon pulmonary valvuloplasty appears feasible, effective and relatively safe initial management & having encouraging immediate & short term results of critical pulmonary valve stenosis in the neonate to grown up children.

**Keywords:** Balloon Pulmonary Valvuloplasty (BPV); neonates & children; critical pulmonary stenosis (PS).

## 1. INTRODUCTION

“Children with critical pulmonary stenosis with right ventricular (RV) pressure equal to or greater than systemic pressure usually critically ill with cyanosis because of right to left shunt at atrial level. They require urgent relief of obstruction at pulmonary valve. Percutaneous balloon pulmonary valvuloplasty (BPV) is the treatment of choice since it was introduced” by Kan et al. in 1982 [1]. “The short- and mid-term results of BPV is very good that nowadays it has become the preferred method of therapy for moderate and severe PS both in children as well as adults” [2,3]. “It is also safe and effective for relief of PS in neonates” [4]. “The success rates of BPV in infants with critical PS have been reported to be 55–94%; however, restenosis has been reported in 17–36% of these patients” [5,6]. The purpose of this study was to review our experience with percutaneous balloon valvotomy in neonates to grown up children with critical pulmonary stenosis or membranous pulmonary atresia with intact ventricular septum.

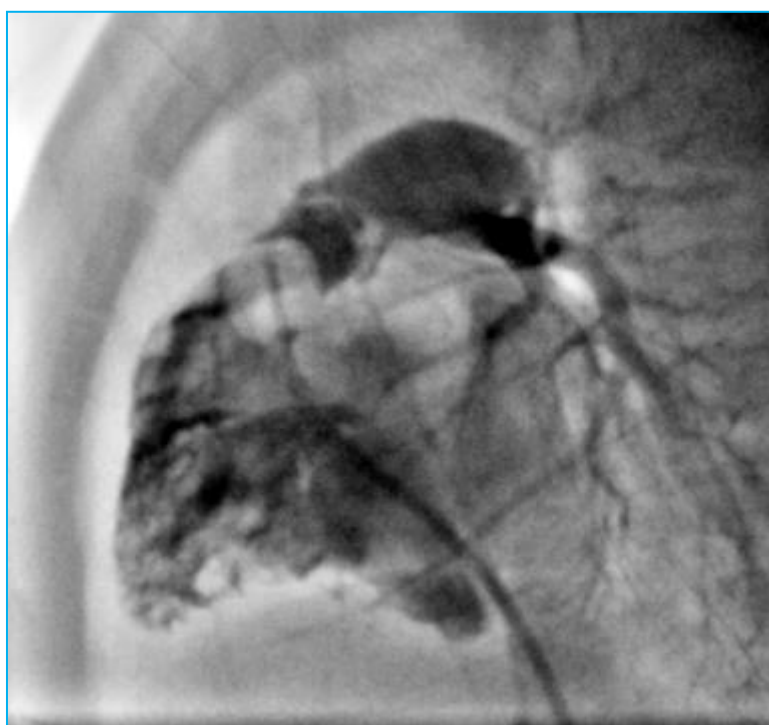## 2. MATERIALS AND METHODS

This retrospective study was conducted in the cardiac centre of Bangladesh Shishu Hospital & Institute between June 2014 to June 2022.

Children with critical pulmonary who presented to us with respiratory distress, metabolic acidosis were admitted to the paediatric cardiac intensive care unit for stabilisation before the procedure. Prostaglandin E1 (PGE1) was initiated in neonates if the level of O<sub>2</sub> saturation was below 75%. The detailed diagnoses were first established by two dimensional and Doppler echocardiography using a Vivid E9 system (GE Medical System, Inc, Horten, Norway).

The procedure was done under general anesthesia & endotracheal intubation. Oxygen saturation, arterial blood O<sub>2</sub> level, and blood pressure were continuously monitored during the procedure. The intracardiac pressure was measured with a fluid-filled catheter system. RV angiogram was done at AP & lateral view to see the valve morphology & to measure annulus size (Fig.1). Before and after BPV, the right ventricle to pulmonary artery pressure gradient were measured. A 4-F or 5-F Judkins catheter was placed in the RVOT, and a 0.014/0.021 guide wire was passed through the pulmonary valve into the ductus arteriosus and the descending aorta, if accessible, or the pulmonary branches.

Clinical and hemodynamic profile, associated cardiac and noncardiac structural anomalies, procedural details and complications, immediate



**Fig. 1. RV angiogram at lateral view showed systolic diming of pulmonary valve**

outcome were collected from patient record file. The right ventricle function, severity of tricuspid and pulmonary regurgitation (PR), residual pulmonary stenosis and intra-atrial shunts in the ASD/PFO levels were evaluated post BPV and subsequently 1 and 6 months afterward in the outpatient follow-up.

Statistical analysis was done by using SPSS version 24. The descriptive statistical analysis of the quantitative variables was carried out by calculating the median, mean and standard deviations. The student paired t test was used to compare pre procedure and post procedure SpO<sub>2</sub>, pressure gradients. A p value <0.05 was considered statistically significant.

### 3. RESULTS

Percutaneous balloon pulmonary valvuloplasty done in 54 children having critical stenosis or membranous pulmonary atresia. This representing 28.4% of the total number of patients referred for BPV in our institute during the given period of the study. Among these neonates were 6(11.8%), infants between 1 month to one year was 30(58.8%), from 1 year to 5 years 10(19.6%), more than 5 years 5(9.8%) (Table 1). The youngest patient was 5 days and eldest was 16 years. Median weight was 6.5 kg, lowest weight was 1.96 kg. Male to female ratio

was 1.3: 1(Fig. 2). Three patients were syndromic. All the neonates were duct dependent & got prostaglandin infusion before the procedure. Most common associated cardiovascular lesion was patent foramen ovale (PFO) which was present in 26 patients, secundum ASD in four patients. This interatrial communication was shunting mostly right to left. Others included small PDA in 18 patients, one patient had tricuspid stenosis (Table 2).

**Table 1. Showed distribution of Age range (N=54)**

Age range	Frequency (Number)	Percentage (%)
Less than 1 month	6	11.8
1 month to 3 months	11	21.6
3 months to six months	4	7.8
Six months to 1 year	15	29.4
1 year to five years	10	19.6
>5 years	5	9.8

The pulmonary balloon size was between 120% and 140% of the diameter of the pulmonary valve annulus in 32 (62.7%) patients and between 100% and 120% in 16 (31.3%) [Fig. 3]. Median size of the balloon was 12 X 30 mm Tyshak II balloon. Predilatation of the balloon for the pulmonary valve was not required in 24 (47%)

cases, while predilation was done in 27 (53%) with smaller to larger balloons sequentially in 2 to 3 steps due to significant residual pulmonary stenosis after the first pulmonary valvuloplasty.

**Table 2. Showed distribution of additional defect (N=54)**

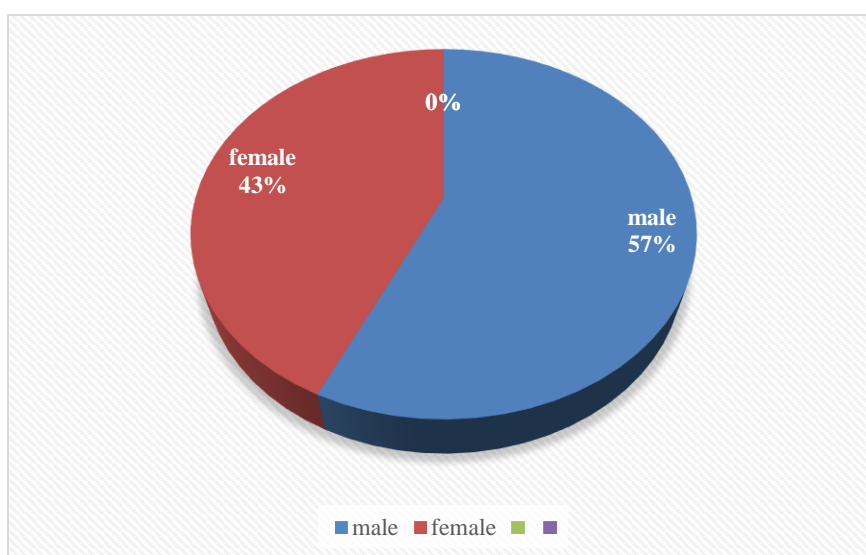
Additional defect	Frequency (Number)	Percentage (%)
Patent foramen ovale (PFO)	19	37.3
Patent ductus arteriosus (PDA)	11	21.6
PFO + PDA	7	13.7
Secundum ASD	4	7.8
Ventricular septal defect (VSD)	2	3.9
Infundibular stenosis	1	2
Tricuspid stenosis	1	2

Mean fluro time was 45 minutes. Baseline SPO<sub>2</sub> was significantly improved after the procedure from 40.55%± 9.8 to 65.30%±9.67 (p<0.05) (Table-3). The right ventricular systolic pressure reduced from an average of 66 ± 7 mm Hg to 16.5 ± 5 mm Hg (P value <0.05) (Table-4). The peak systolic gradient reduced from an average of 66 ± 7 mm Hg to 16.5 ± 5 mm Hg (P value <0.05) (Table 5). The pressure gradient was decreased to less than 30 mm Hg in 49 children (76.4%) which was considered as optimal effect, residual gradient between 30 – 50 mm Hg was seen in 7 patients (13.7%) which was considered

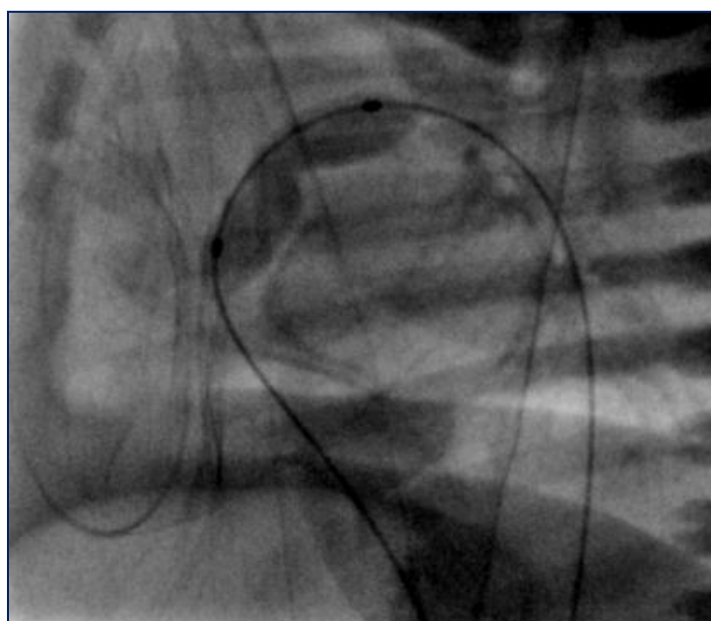
as suboptimal effect & residual gradient more than 50 mm Hg was seen in 5 patients (9.8%) which was considered as poor effect.

No major complication occurred except mild PR, RV dysfunction, transient bradycardia. Two patients died due to sudden cardiac arrest after six hours of procedure. It was thought due to pulmonary over circulation or due to unrecognised ventricular arrhythmia. Thereafter all critical PS patients ventilated & sedated for 24 hours after procedure & low dose diuretics was given. Additional three patients died due to sepsis, aspiration pneumonia. One patient procedure could not be done due to failure to take vascular access at the beginning of our series [16].

“Transcatheter intervention for pulmonary atresia with intact ventricular septum (IVS) is an effective but technically difficult primary palliative treatment in newborns. Three neonates with membranous pulmonary atresia with intact IVS underwent pulmonary valve perforation using coronary total occlusion (CTO) guide wire conquest Pro. We also incorporate ductal stenting as RV was intermediate or borderline. Mean age was 29 days & mean weight was 3 Kg. Detailed echocardiographic examination focused on right ventricle size, and tricuspid valve morphology and coronary sinusoids were performed in all the patients before the intervention. Right ventricular systolic pressure fell significantly from 112±21 to 49.6±9.7 mm Hg (p value 0.001)” [16].



**Fig. 2. Distribution of gender**



**Fig. 3. Showed balloon angioplasty of pulmonary valve**

**Table 3. Showed Improvement of SpO2 after BPV (N=54)**

<b>SpO2</b>	<b>Mean ± (SD) (%)</b>	<b>P Value</b>
SpO2 before procedure	40.55%± 9.8	0.012
Spo2 at discharge	65.30%±9.67	

**Table 4. Showed reduction of RVSP before & after procedure (N=54)**

<b>Right ventricular systolic pressure(RVSP)</b>	<b>Mean ± (SD) (%)</b>	<b>P Value</b>
Before procedure	107.68 ± 39.9 mm Hg	0.000
After procedure	54.46 ± 24.8 mm Hg	

**Table 5. Showed Reduction of peak to peak systolic gradient before & after procedure (N=54)**

<b>Peak to peak systolic gradient between RV to PA</b>	<b>Mean ± (SD) (%)</b>	<b>P Value</b>
Before procedure	85.70 ± 38.2	0.000
After procedure	27.2± 24.6	

**Table 6. Showed severity of residual stenosis at 1 month follow up (N=10)**

<b>Severity of residual stenosis</b>	<b>Frequency (number)</b>	<b>Percent (%)</b>
Mild residual stenosis	5	9.8
Moderate residual stenosis	4	7.8
Severe residual stenosis	1	2

**Table 7. Showed severity of residual stenosis at 6 month follow up (N=5)**

<b>Severity of residual stenosis</b>	<b>Frequency (number)</b>	<b>Percent (%)</b>
Mild residual stenosis	4	7.8
Moderate residual stenosis	1	2
Severe residual stenosis	Nil	Nil

At 1 month follow up 12 patients had mild residual stenosis, 5 had moderate residual pulmonary stenosis, 2 had severe residual pulmonary stenosis (Table 6). Among severe residual pulmonary stenosis one was our eldest patient of 16 years other one was membranous pulmonary atresia patient. Both underwent repeat valvuloplasty after 6 months of initial procedure. At 6 month follow up four patient had mild residual pulmonary stenosis & one had moderate pulmonary stenosis (Table 7). Among three membranous pulmonary atresia patient one patient who required repeat valvuloplasty, stented duct closed on its own. Other two patients require addition of bidirectional Glenn shunt. Moderate pulmonary regurgitation (PR) was seen among 7 patients & mild in 14 patients (39%) at 1 month follow up. The incidence of pulmonary regurgitation was declined to mild pulmonary regurgitation in 8 patients (15%) at 6 months after procedure. Mild RV systolic dysfunction was present six patients & moderate RV systolic dysfunction was still present in our eldest patient of 16 years at 6 month follow up. Bidirectional shunt across ASD was persistent in twenty-two patients at 1 month follow up and twelve patients at six month follow up due to impaired relaxation of RV.

#### 4. DISCUSSION

“Pulmonary stenosis occurs in approximately 6.6/1000 live births and slightly higher in Asian countries compared to Europe and the United States” [7,8]. For a successful balloon pulmonary valvuloplasty it is crucial to select appropriate balloons. Several previous studies have focused “on the relationship between balloon selection and valve annulus; the most widely accepted ratio is 1.2–1.4, which has already been mentioned in some guidelines and recommendations” [9,10] We use this ratio in our clinical practice in 62.7% cases as well. The significant immediate reduction of both the Right ventricular systolic pressure (RVSP) and the Pressure gradient across the RVOT in our study was consistent with the data published by Karagoz et al. [11]. Saad et al., defined immediate success rate as the drop in the RVSP to less than or equal to 50% of the baseline measurement & was achieved in 85% of the cases of critical pulmonary stenosis in infants [12]. In our series we have shown the pullback pressure gradient between PA to RV was decreased to less than 30 mm Hg in 49 children (76.4%) which was considered as optimal effect. There was also a progressive decrease in the

pressure gradient across the RVOT throughout the follow-up period from 12 patients with mild residual stenosis, 5 patients with moderate residual pulmonary stenosis & 2 patients with severe residual pulmonary stenosis at 1 month follow up to 4 patients with mild residual pulmonary stenosis & 1 patient with moderate residual stenosis after 6 months. This was consistent with the data published in other age groups like that of Sharieff et al., who reported “a decrease in the PG from  $33.5 \pm 9.7$  mm Hg immediately after BPV to  $18.6 \pm 3.4$  mm Hg at follow-up” [13]. This finding might be explained by the gradual regression of infundibular hypertrophy. Werynski et al., reported PR in 39.5% of children with critical PS immediately after BPV which was consistent with our series [14]. We report a gradual decline in the incidence of PR to about 15% at 6 months follow up which was consistent with Saad et al. series [12]. Though BPV in older age group reported with almost no mortality but critical pulmonary stenosis in mostly neonates, infants & early childhood in our series showed mortality rate of 9.2 % compared to 8% of the patients as reported by Tabatabaei et al. [15] and 14% of the patients as reported by Karagoz et al. [11].

#### 5. CONCLUSION

Balloon pulmonary valvuloplasty appears feasible, effective and relatively safe initial management of critical pulmonary valve stenosis in the neonate to grown up children. Immediate & short term results are encouraging. BPV is likely to provide definitive therapy in neonates, infants & grown up children.

#### CONSENT

Informed consent was obtained from the parents.

#### ETHICAL APPROVAL

It is not applicable.

#### COMPETING INTERESTS

Authors have declared that no competing interests exist.

#### REFERENCES

1. Kan JS, White RI Jr., Mitchell SE, Gardner TJ. Percutaneous balloon valvuloplasty: A new method for treating congenital

- pulmonary-valve stenosis. *N Engl J Med.* 1982;307:540-2.  
DOI: 10.1056/NEJM198208263070907.
2. Ray DG, Subramanyan R, Titus T, Tharakan J, Joy J, Venkitachalam CG, Kumar A, Balakrishnan KG. Balloon pulmonary valvoplasty: factors determining short- and long-term results. *Int. J. Cardiol.* 1993;40(1):17–25.
  3. Shrivastava S, Kumar RK, Dev V, Saxena A, Das G. Determinants of immediate and follow-up results of pulmonary balloon valvuloplasty. *Clin. Cardiol.* 1993;16(6): 497–502.
  4. Gournay V, Piechaud J, Delogu A, Sidi D, Kachaner J. Balloon valvotomy for critical stenosis or atresia of pulmonary valve in newborns. *J. Am. Coll. Cardiol.* 1995;26: 1725–1731.
  5. Caspi J, Coles JG, Benson L, Freedom RM, Burrows EM, Smallhorn JF, Trusler GA, Williams WG. Management of neonatal critical pulmonic stenosis in the balloon valvotomy era. *Ann. Thorac. Surg.* 1990;49:273–278.
  6. Talsma M, Witsenburg M, Rohmer J, Hess J. Determinants for outcome of balloon valvuloplasty for severe pulmonary stenosis in neonates and infants up to six months of age. *Am. J. Cardiol.* 1993;71: 1246–1248.
  7. Derrick G, Bonhoeffer P, Anderson R. Pulmonary stenosis. In: Anderson RH, editor. *Paediatric Cardiology*. 3rd ed. Philadelphia, USA: Elsevier Ltd. 2010: 895-915.
  8. van der Linde D, Konings EE, Slager MA, Witsenburg M, Helbing WA, Takkenberg JJ, et al. Birth prevalence of congenital heart disease worldwide: A systematic review and meta-analysis. *J Am Coll Cardiol.* 2011;58:2241-7.  
DOI: 10.1016/j.jacc.2011.08.025.
  9. Committee on Congenital Heart Diseases IMBO. Interventional treatment of common congenital heart diseases: The common view of Chinese medical experts. Part Four: Percutaneous balloon valvuloplasty for pulmonary and aortic valve stenosis. *J Interv Radiol* 2011;20:253-60.  
DOI:10.3969/j.issn.1008-794X.2011.04.001.
  10. Rao PS. Percutaneous balloon pulmonary valvuloplasty: State of the art. *Catheter Cardiovasc Interv* 2007;69:747-63.  
DOI: 10.1002/ccd.20982.
  11. Karagoz T, Asoh K, Hickey E, Chaturvedi R, Lee KJ, Nykanen D, Benson L. Balloon dilatation of pulmonary valve stenosis in infants less than 3 Kg: a 20-year experience. *Catheter Cardiovasc. Interv.* 2009;74(5):753–761.
  12. Saad MH, Roushdy AM, Elsayed MH. Immediate- and medium-term effects of balloon pulmonary valvuloplasty in infants with critical pulmonary stenoses during the first year of life: A prospective single center study. *Journal of the Saudi Heart Association.* 2010;22:195–201.
  13. Sharieff S, Shah-e-Zaman K, Faruqi AM. Short and intermediate term follow up results of percutaneous transluminal balloon valvuloplasty in adolescents and young adults with congenital pulmonary valve stenosis. *J. Invasive Cardiol.* 2003; 15(9):484–487.
  14. Werynski P, Rudzinski A, Krol-Jawien, W., Kuzma J. Percutaneous balloon valvuloplasty for the treatment of pulmonary valve stenosis in children—a single center experience. *Kardiol. Pol.* 2009;67(4):369–375.
  15. Tabatabaei H, Boutin C, Nykanen DG, Freedom RM, Benson LN. Morphologic and hemodynamic consequences after percutaneous balloon valvotomy for neonatal pulmonary stenosis: medium term follow up. *J. Am. Coll. Cardiol.* 1996;27 (2):473–478.
  16. Rima R, Al Mamun MA, Khan MK, Munshi AS, Jabbar A, Shaha C. Transcatheter cardiac intervention in neonates: Experience From a Tertiary Care Centre in Bangladesh. *Medico Research Chronicles.* 2023;10(2):178-87.

© 2023 Rima et al.; This is an Open Access article distributed under the terms of the Creative Commons Attribution License (<http://creativecommons.org/licenses/by/4.0>), which permits unrestricted use, distribution, and reproduction in any medium, provided the original work is properly cited.

*Peer-review history:*  
The peer review history for this paper can be accessed here:  
<https://www.sdiarticle5.com/review-history/109352>