

## Antegrade jj stenting after percutaneous renal procedures: The 'pull and push' technique

Jaideep M. Ratkal & Elias Sharma

To cite this article: Jaideep M. Ratkal & Elias Sharma (2015) Antegrade jj stenting after percutaneous renal procedures: The 'pull and push' technique, Arab Journal of Urology, 13:2, 91-93, DOI: [10.1016/j.aju.2014.11.001](https://doi.org/10.1016/j.aju.2014.11.001)

To link to this article: <https://doi.org/10.1016/j.aju.2014.11.001>



© 2014 Arab Association of Urology



Published online: 05 Apr 2019.



Submit your article to this journal [↗](#)



Article views: 269



View related articles [↗](#)



View Crossmark data [↗](#)



**Arab Journal of Urology**  
(Official Journal of the Arab Association of Urology)

[www.sciencedirect.com](http://www.sciencedirect.com)



**STONES/ENDOUROLOGY**  
**POINT OF TECHNIQUE**

# Antegrade JJ stenting after percutaneous renal procedures: The ‘pull and push’ technique



Jaideep M. Ratkal <sup>a,\*</sup>, Elias Sharma <sup>b</sup>

<sup>a</sup> Department of Urology, Karnataka Institute of Medical Sciences, India

<sup>b</sup> Department of Urology, Government Medical College, Jammu, India

Received 6 September 2014, Received in revised form 18 October 2014, Accepted 8 November 2014  
Available online 1 December 2014

## KEYWORDS

PCNL;  
Antegrade;  
JJ stent

## ABBREVIATIONS

PCNL, percutaneous  
nephrolithotomy

**Abstract** A JJ stent is inserted antegradely after percutaneous renal procedures like percutaneous nephrolithotomy (PCNL) for renal calculus disease, and for endopyelotomy for pelvi-ureteric junction obstruction. We describe a technique for antegrade stent insertion after PCNL.

© 2014 Arab Association of Urology. Production and hosting by Elsevier B.V. This is an open access article under the CC BY-NC-ND license (<http://creativecommons.org/licenses/by-nc-nd/3.0/>).

## Introduction

Percutaneous nephrolithotomy (PCNL) is a recommended intervention for renal stones of > 2.5 cm. Percutaneous procedures are also used to gain access to large upper ureteric stones and to the PUJ for antegrade endopyelotomy. Stent insertion is an important adjunct

in all these procedures, and with the advent of tubeless PCNL insertion has become an integral part of the procedure [1]. A stent can be inserted by either a retrograde or antegrade method, with antegrade stenting having the distinct advantage of minimal urethral manipulation and ease of insertion. Various techniques like the reverse-zebra technique [3] or passing the stent over a through-and-through guidewire [4] have been described for antegrade stent insertion. We describe a simple, easy to master technique that can be used in every situation.

## Technique

The percutaneous access to the pelvi-calyceal system is obtained as per the standard description, with puncture and tract dilatation done under fluoroscopic guidance.

\* Corresponding author at: Department of Urology, Karnataka Institute of Medical Sciences, Hubli 580024, India. Tel.: +91 8362202049, mobile: +91 9449854417.


E-mail address: [jaidepratkal@gmail.com](mailto:jaidepratkal@gmail.com) (J.M. Ratkal).

Peer review under responsibility of Arab Association of Urology.

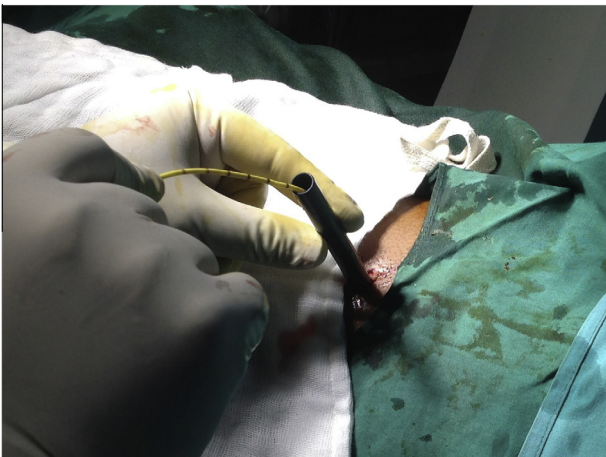


Production and hosting by Elsevier

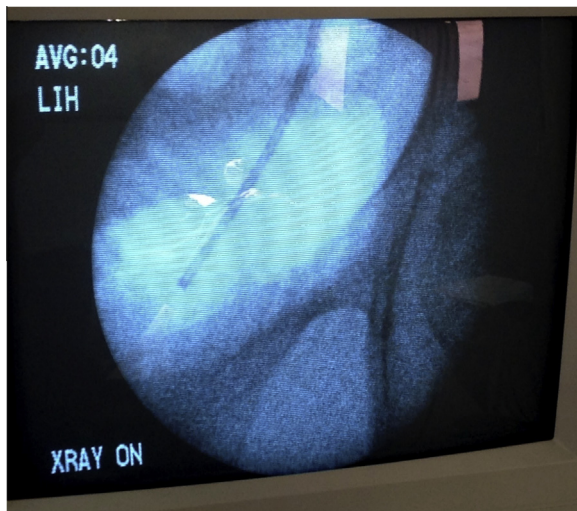
An open-ended ureteric catheter is placed cystoscopically, to opacify the pelvi-calyceal system for the initial puncture, before placing the patient prone.



**Figure 1** The renal end of the ureteric catheter being retrieved through the Amplatz sheath.

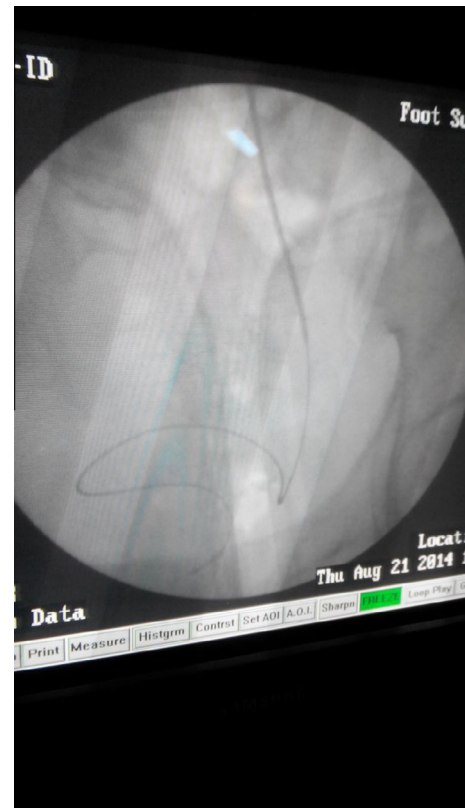


**Figure 2** The ureteric catheter being pulled out of the Amplatz sheath under fluoroscopic guidance.

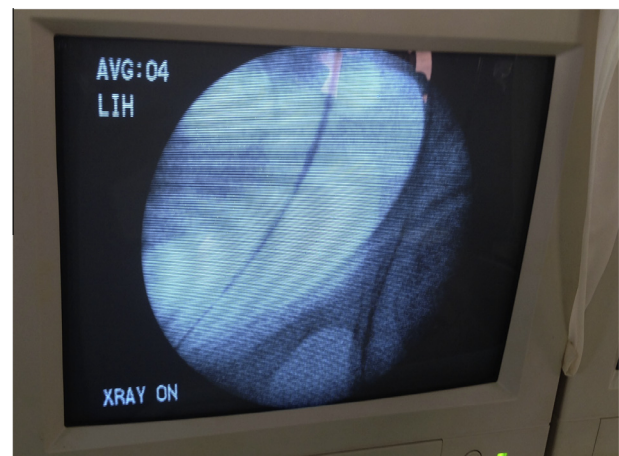


**Figure 3** A fluoroscopic image showing the ureteric catheter just above the symphysis pubis.

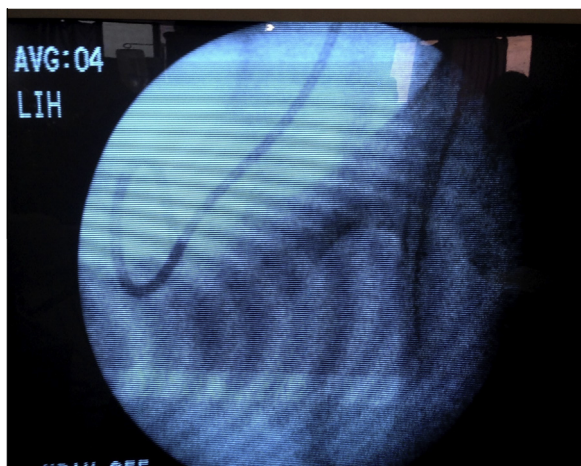
At the end of the procedure, with the fluoroscope positioned over the bladder, the renal end of the ureteric catheter is grasped and brought out of the Amplatz sheath (Figs. 1 and 2). Under fluoroscopic guidance the ureteric catheter is gradually pulled until the lower end of the ureteric catheter is seen just above the symphysis on fluoroscopy (Fig. 3). A zebra or any other suitable guidewire is passed through the ureteric catheter in an antegrade fashion, until the floppy end of the guidewire is seen to curl in the bladder (Fig. 4). The ure-



**Figure 4** The guidewire being passed through the ureteric catheter allowing it to curl.



**Figure 5** The stent being passed over the guidewire.



**Figure 6** A fluoroscopic image showing a well-positioned lower end of the JJ stent.

teric catheter is withdrawn as the guidewire is being passed. The JJ stent is passed antegradely over the guidewire under fluoroscopic guidance, using the nephroscope (Figs. 5 and 6). We normally do not keep the nephrostomy tube unless indicated.

Using this technique in >300 consecutive PCNL, antegrade ureteroscopy or endopyelotomy procedures, we have encountered no difficulty in placing the stent antegradely.

## Discussion

The insertion of a JJ stent is an adjunctive procedure for various percutaneous procedures, and to a large extent eliminates the need for a nephrostomy, hence reducing hospitalisation and the need for postoperative analgesia [1]. Although stent insertion necessitates an additional procedure for its removal, the same can be obviated by using tethered stents [2,5].

A stent can be inserted after percutaneous procedures using retrograde or antegrade techniques. Antegrade stenting has an advantage over retrograde stenting, as it eliminates the need for patient repositioning from prone to supine.

The reverse-zebra technique [3] involves passing the stiff end of a guidewire retrogradely through the ureteric catheter at the urethral end and retrieval through the Amplatz sheath. Antegrade stenting is done after positioning the guidewire and withdrawing the urethral end of ureteric catheter. This technique involves manipulation at the urethral end, although less than that in the through-and-through technique.

In the latter technique [4] the guidewire is passed retrogradely through the ureteric catheter and retrieved through the Amplatz sheath. The stent is inserted antegradely over the guidewire after withdrawing the ureteric catheter. The technique involves considerable manipulation at the urethral end and positioning the lower end is sometimes difficult, as the stent can be pushed too far down, into the prostatic urethra. We used this technique previously but there was significant urethral bleeding in a few patients due to an inadvertent urethrotomy while withdrawing the guidewire, and this led us to abandon the technique and devise the 'pull and push' technique.

In our technique the urethral manipulation is totally eliminated, and the floppy end of the guidewire is passed down after absolutely confirming the position of the ureteric catheter by the injection of contrast medium. We feel that antegrade stenting using our technique is considerably quicker as the urethral manipulation is eliminated. The technique is also simple and easy to learn.

In conclusion, the 'pull and push' technique of antegrade stenting after a percutaneous renal procedure is simple, easy and useful to learn and practise as an adjunct in various percutaneous renal procedures.

## Conflict of interest

None declared.

## Source of Funding

None.

## References

- [1] Telha KA, Alba'adani TH, Alkohlany KM, Al-Adimy AO, Alnono IH. Tubeless percutaneous nephrolithotomy with double-J stent compared with external ureteral catheter to decrease postoperative complications. *Saudi Med J* 2010;31(10):1137–40.
- [2] Agrawal MS, Sharma M, Agarwal K. Tubeless percutaneous nephrolithotomy using antegrade tether: a randomized study. *J Endourol* 2014;28:644–8.
- [3] Maheshwari PN, Andankar MG, Khera R, Hegde S, Bansal M. Antegrade JJ-stenting after percutaneous renal procedures. The reverse zebra technique. *Indian J Urol* 2001;17:191–2.
- [4] Lumerman JH, Smith AD. Technique of endopyelotomy. In: Yachia D, editor. *Stenting the urinary system*. Oxford: Isis Medical Media; 1998. p. 181–9.
- [5] Shpall AI, Parekh AR, Bellman GC. Tubeless percutaneous nephrolithotomy with antegrade stent tether: clinical experience. *J Endourol* 2007;21:973–6.