

# Peritumoural and Intratumoural Distribution of Langerhan Cell in Oral Squamous Cell Carcinoma and its Association with Known Prognostic Factors

SANDHRA PAPPARATH USMAN<sup>1</sup>, DEEPTI RAMAKRISHNAN<sup>2</sup>, S DIVYA<sup>3</sup>

## ABSTRACT

**Introduction:** Oral Squamous Cell Carcinoma (OSCC) accounts for about 2/3<sup>rd</sup> of the Head and Neck Squamous Cell Carcinomas (HNSCC). It is the sixth most common cancer worldwide and the third most common cancer in developing countries including India. More than half the HNSCC patients have advanced disease at the time of diagnosis and overall long-term survival is low (50%), despite aggressive therapeutic regimens. This has demanded the need for prognostic indicators that can be used to improve the ability to select a more individualised approach for treatment relative to the risks of recurrence, metastases and death.

**Aim:** To study the intratumoural and peritumoural distribution and density of Langerhans Cells (LC) in OSCC using Immunohistochemistry (IHC) markers Cluster of Differentiation-1a (CD1a) and Langerin and to study its association with known prognostic factors.

**Materials and Methods:** This was a hospital-based cross-sectional study conducted at the Department of Pathology, Amala institute of Medical Sciences, Kerala, India during a period of 18 months, from January 2019 to June 2020. In total, 28 specimens of wide local excision with cervical lymph node dissection done for OSCC were enrolled in the study. Small biopsy samples and cases who had undergone neoadjuvant treatment as well as cases of recurrent OSCC were excluded.

Clinical details were obtained from the patients' case files. The immunohistochemical staining for LCs using CD1a and Langerin was done. The distribution of LCs was compared to the tumour grade and lymph node status along with lymphovascular and perineural invasion. Statistical analysis was performed using sample t-test after identifying normality of distribution. The p-value of <0.05 was taken as significant.

**Results:** Fourteen cases of well differentiated and 14 cases of moderate to poorly differentiated OSCC were selected for the study. The LC distribution in these cases were compared to prognostic factors like histological grade, Lymphovascular Invasion (LVI), perineural invasion, tumour size, depth of invasion, T stage and lymph node status. A significant positive association was observed between the tumour differentiation and peritumoural CD1a positive cell density (p-value: 0.001). Further, a negative association was also established between the lymph node staging and peritumoural CD1a positive cell density (p-value: 0.004). There was no association between the LC density and presence of lymphovascular or perineural invasion in OSCC.

**Conclusion:** A depleted peritumoural LC density in OSCC reflects poor tumour immunity, associated with higher grade and higher stage of lymph node metastasis. LC density may hence be of prognostic value in OSCC.

**Keywords:** Dendritic cells, Cluster of differentiation1a, Langerin

## INTRODUCTION

The OSCC accounts for about 2/3<sup>rd</sup> of the HNSCC. It is the sixth most common cancer worldwide and the third most common cancer in developing countries like India [1,2]. In India, OSCC is the most common cancer among men and fourth most common among women, contributing about 2/3<sup>rd</sup> of the global burden [3]. The prognosis of OSCC is related to various factors such as histological grade, tumour location, tumour size, involvement of adjacent tissues and metastasis at the time of diagnosis [4-10]. The GLOBOCAN project in 2018 estimated a global age-standardised incidence rate of 3.5 per 1,00,000 population per year and global mortality rate of 1.77 deaths per 1,00,000 population per year [11]. More than half of all HNSCC patients have advanced disease at the time of diagnosis with a poor overall survival rate of five years and a low overall long-term survival (50%), despite aggressive therapeutic regimens [12,13]. This has demanded the need for prognostic indicators that can be used to improve the ability to select a more individualised approach for treatment relative to the risks of recurrence, metastases and death. LCs belongs to a population of antigen presenting cells in the epidermis and mucous membranes which may play an important role in the

immunological defence mechanism against epithelial tumours [4]. Several immunohistochemical markers targeting LCs have been identified, such as S100, Cd1a, CD83, Langerin (CD207), CD208, CD80, CD11c, CD86 and HLA -DR (Human Leukocyte Antigen - DR isotype) [14]. Langerin and CD1a are specific immunohistochemical markers of LCs [15]. Present study was aimed to identify the distribution of LCs in OSCC intratumourally and peritumourally and compare it with the established prognostic and theranostic factors of OSCC including tumour size, tumour grade, tumour thickness, LVI and cervical lymph node metastasis to evaluate the prognostic impact of LCs in OSCC.

## MATERIALS AND METHODS

This was a descriptive cross-sectional study conducted at the Department of Pathology, Amala Institute of Medical Sciences, Kerala, India. The study was conducted during a period of 18 months from January 2019 to June 2020. The cases histologically diagnosed as OSCC during this period were enrolled in the study. A total of 28 cases were studied, after obtaining approval from the Institutional Research and Ethical Committee (IEC no: AIMSIEC/27/2018).

**Inclusion criteria:** All wide excision specimens of OSCC with lymph node dissection, received at the Department of Pathology from January 2019 to June 2020 were included in this study.

**Exclusion criteria:** Cases that underwent neoadjuvant chemotherapy or radiotherapy for OSCC, recurrent cases of OSCC and small biopsy samples of OSCC were excluded from this study.

**Study procedure:** A total of 28 wide excision specimens of OSCC along with lymph node dissection received at the Department of Pathology, Amala Institute of Medical Sciences, satisfying both the inclusion and exclusion criteria were enrolled for the study. A predesigned proforma was used to document the relevant patient variables and pathological details required for the study. Relevant clinical information (age, gender, tobacco smoking, alcohol consumption), were taken from the case records and histopathology requisition forms of the patient. Grossing of specimens was performed according to standard College of American Pathologists (CAP) protocol [16]. Histological diagnosis were rendered on properly oriented, formalin fixed, paraffin embedded, Haematoxylin and Eosin stained sections (4  $\mu$  thickness). Paraffin blocks containing tumour proper along with adequate peritumoural stroma were selected for each case. A 4  $\mu$  thick section were cut and mounted on three glass slides for each case. H&E staining was done on one of the sections. On the other two, IHC staining was performed using the markers Rabbit Monoclonal Anti-CD1a Antibody and Rabbit Monoclonal Anti-Langerin Antibody. LCs were assessed following IHC staining.

Relevant findings (histological grade, LVI, perineural invasion, tumour size, depth of invasion, TNM staging and lymph node status) were recorded.

The cases were reviewed and morphologically classified into two groups-well differentiated OSCC and moderately to poorly differentiated OSCC, similar to the study by Jardim JF et al., [14].

Tumours were categorised based on their size as: 0-2 cm, >2-4 cm and >4 cm, as categorised in the TNM staging. Lymphovascular and perineural invasion were assessed on H&E sections.

Maximum depth of invasion was determined by the infiltration of the tumour as measured from the nearest uninvolved mucosal surface. They were categorised as: 0-0.5 cm; >0.5-1 cm and >1 cm [16].

Staging of the tumours were done based on the AJCC staging system, 8<sup>th</sup> edition [17].

Evaluation of LCs on IHC stained slides: Cells with membranous staining with CD1a and Langerin were considered as CD1a positive and Langerin positive cells, respectively, as per reagent specifications. Four fields of 1 mm<sup>2</sup> for both, intratumoural and peritumoural LCs were selected. The results were expressed as the mean positive count staining of the four areas analysed that were translated into the density of cells per mm<sup>2</sup> [14].

## STATISTICAL ANALYSIS

Data was entered in MS Excel worksheets and analysed using Statistical Package for the Social Sciences (SPSS) version 23.0 statistical software. Descriptive and inferential statistical analysis was carried out. Results on continuous measurements were presented on mean standard deviation and results on categorical measurements were presented in number (%). Significance assessed at 5% level. Normality of data was tested using Shapiro-Wilk test. If normal, the difference between intratumoural and peritumoural density of LCs was analysed by independent sample t-tests. The statistical significance was considered when p-value <0.05.

## RESULTS

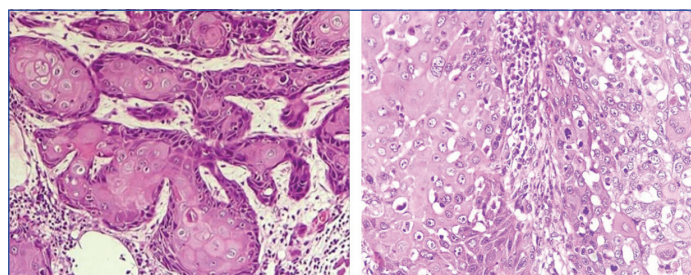
The patient age ranged from 42 to 82 years, with the maximum number of cases (11 cases) in this study between the age group of 61-70 years, closely followed by nine patients between the ages of 51 and 60. Six of the remaining patients were over the age of

70 and only two patients below 50 years of age. The mean age at diagnosis was 63.03 $\pm$ 9.57 years. The study group of 28 patients showed a male predominance with 19 (67.86%) males and nine (32.14%) females.

Thirteen of 28 patients (46.4%) gave history of smoking (all of which were males) while the remaining were never smokers. Seven patients (25%) gave history of alcoholism (all of which were males) and the other 21 (75%) patients were teetotallers.

The most common site involved was the tongue, accounting for 16 cases (57.14%). The rest of the sites in order of their incidence were Buccal mucosa: 4 (14.28%), Alveolar ridge: 3 (10.71%), Floor of mouth: 2 (7.14%), Angle of mouth: 2 (7.14%) and Lip: 1 (3.57%).

There were an equal number of 14 cases (50%) each of well differentiated OSCC [Table/Fig-1] and moderately to poorly differentiated OSCCs. Among the latter category, 13 cases were moderately and one case was poorly differentiated OSCC [Table/Fig-2].



**[Table/Fig-1]:** Well differentiated Oral Squamous Cell Carcinoma (OSCC) (H&E; 40X).  
**[Table/Fig-2]:** Poorly differentiated Oral Squamous Cell Carcinoma (OSCC) (H&E; 10X). (Images from left to right).

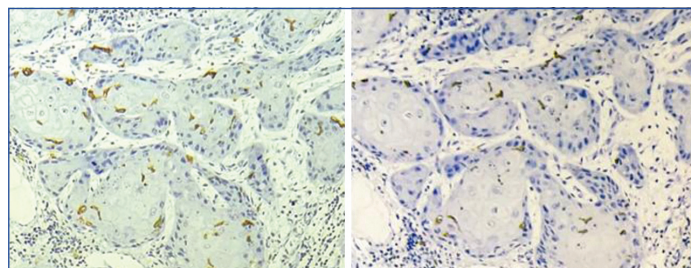
Only 2 (7.14%) cases showed evidence of LVI and 6 (21.4%) cases showed evidence of perineural invasion. Majority of the tumours were of size within 4 cm in maximum diameter with 13 cases of size 0-2 cm and 12 cases of size >2-4 cm. Twelve cases showed a depth of invasion of less than or equal to 0.5 cm and nine cases had a depth of invasion of over 1 cm.

T stage: Of the 28 cases, 9 (32%) belonged to T1 category, 11 (39%) to T2, 4 (14.5%) to T3 and 4 (14.5%) to T4 categories.

N stage: A 78% of the cases accounting for 22 of the 28 cases showed no nodal involvement. Of the remaining six cases that showed nodal involvement, 3 (11%) belonged to N1, 2 (7%) belonged to N2 and 1 (4%) of the cases belonged to N3 nodal status.

M stage: None of the cases show evidence of metastasis.

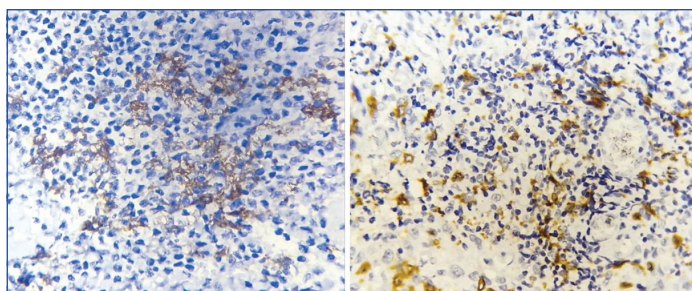
Association between the pathological parameters (histological grade, LVI, perineural invasion, tumour size, depth of invasion, TNM staging and lymph node status) and the density of intratumoural and peritumoural LCs were analysed [Table/Fig-3-6].



**[Table/Fig-3]:** IHC: Intratumoural Langerhans Cells (LC) highlighted by CD1a (40X).  
**[Table/Fig-4]:** IHC: Intratumoural Langerhans Cells (LC) highlighted by Langerin (40X). (Images from left to right).

Statistically, peritumoural CD1a positive cell distribution showed significant negative association with histological grade, with a p-value of 0.001. Similar association was also noted with intratumoural LC distribution without statistical significance. The LC distribution showed no association to the presence or absence of LVI, perineural invasion or tumour size. There was a significant decrease in peritumoural LC density in tumours with a depth of invasion of more than 1 cm than





**[Table/Fig-5]:** Peritumoural Langerhans Cells (LC) highlighted by CD1a (10X).  
**[Table/Fig-6]:** Peritumoural Langerhans Cells (LC) highlighted by Langerin (10X).  
 (Images from left to right).

Parameter	Category	No	IT CD1a+cells	p-value	PT CD1a+cells	p-value	IT Langerin+cells	p-value	PT Langerin+cells	p-value
Tumour grade	WD	14	21.033±20.016	0.111	10.827±6.192	0.001	13.411±7.346	0.225	10.861±8.563	0.445
	MPD	14	11.494±8.162		3.571±3.544		9.964±7.324		7.970±11.009	
LVIN	No	26	16.765±16.254	0.587	7.599±6.235	0.111	12.25±7.383	0.156	9.871±10.014	0.288
	Yes	2	9.750±3.889		2.000±0.00		4.375±1.944		3.5000±2.121	
PNI	No	22	17.612±17.508	0.774	7.867±6.621	0.287	11.125±7.410	0.471	8.261±7.705	0.470
	Yes	6	11.320±4.172		4.750±3.574		13.750±7.697		13.647±15.515	
Tumour size	0-2 cm	13	14.465±16.0852	0.239	8.141±7.1193	0.118	11.962±6.6480	0.329	11.987±12.2259	0.221
	2.1-4 cm	12	20.236±16.7747		7.458±5.4739		13.000±8.3380		8.150±7.1399	
	>4 cm	3	8.167±6.4533		2.083±0.8779		5.025±4.5207		3.333±2.8867	
DOI	0-0.5 cm	12	11.525±6.7751	0.216	7.444±4.7770	0.050	11.583±7.7410	0.268	10.979±12.5047	0.269
	0.6-1 cm	7	23.047±20.2231		9.321±4.5614		15.571±7.5425		10.686±7.2102	
	>1 cm	9	17.306±19.8474		5.222±8.5654		8.806±6.1336		6.343±7.3288	
T stage	1	9	10.006±3.6319	0.038	6.287±4.3103	0.168	11.611±6.8512	0.271	12.583±13.8254	0.077
	2	11	19.644±17.6239		6.864±4.6197		13.5±8.5980		8.664±7.0848	
	3	4	29.563±25.8235		7.438±9.0654		13.063±6.0772		11.521±8.6379	
	4	4	6.750±4.3922		2.313±0.8509		5.500±4.4535		2.250±2.0616	
Lymph node	N0	22	17.21±17.076	0.091	6.82±5.267	0.004	12.386±7.353	0.204	10.265±10.610	0.077
Status	N1	3	19.50±8.792		4.917±4.018		14.583±7.142		10.35±4.332	
	N2	2	0.875±0.176		1.375±0.176		2.625±3.005		0.875±1.237	
	N3	1	12.5		3.5		5.75		5	

**[Table/Fig-7]:** Clinicopathological parameters of Oral Squamous Cell Carcinoma (OSCC) and its association with Langerhans Cell (LC) distribution and density. WD: Well differentiated; MPD: Moderately to poorly differentiated; LVIN: Lymphovascular invasion; PNI: Perineural invasion; DOI: Depth of invasion; IT: Intratumoural; PT: Peritumoural; The format of the table is referenced from study done by Jardim JF et al., [8].

in those less than 1 cm (p-value: 0.05). No significant difference was noted in intratumoural LC density and depth of invasion.

The intratumoural LCs showed an increase in density with tumour stage (T1 to T3), which reflected increase in intratumoural LCs with increase in tumour size and depth. However, T4 stage was associated with least intratumoural LC density (p-value: 0.038). There was no association between peritumoural LC density and T stage. The LC distribution was compared to the lymph node status. Peritumoural LCs showed a negative association with the lymph node (N) status (p-value 0.004). No similar association was noted with intratumoural LC density [Table/Fig-7].

## DISCUSSION

The OSCC is one of the leading causes of mortality worldwide. This may be attributed to the high propensity for local and nodal metastasis of this tumour. Hence, this neoplasm has been extensively studied to determine its various prognostic factors. Over the past decade, the role of inflammatory cells in various tumours is being explored. Immunology of oral diseases has been focused on tumour antigens and lymphocytes. Of equal importance are Antigen Presenting Cells (APCs) such as LCs of the epithelium that are initiators and modulators of immune response.

In this study, authors had compared the density and distribution of LCs in OSCC, to various clinicopathological parameters. IHC markers CD1a and Langerin (CD207) to identify the LCs in sections were used.

## Histological Grade

A total of 28 cases of OSCC were selected for the current study. LC density in Intratumoural and Peritumoural zones were assessed using IHC stains: CD1a and Lanegrin. A higher density of peritumoural CD1a-positive cells was observed in well differentiated OSCC as compared to the moderate to poorly differentiated group of OSCC, which showed statistical significance (p-value: 0.001). Although not statistically significant, a similar distribution proportion was seen in peritumoural Langerin positive cells as well. In their study, Jardim JF et al., conducted the study using IHC markers CD1a and CD83 to identify LC. They identified a tendency to statistical significance between the diminished counts of intratumoural CD83+with

histological grade (p-value=0.08) [14]. In a study by Lasisi TJ et al., the number of LCs (highlighted by CD1a) was significantly reduced in high-grade OSCC as compared to low grade OSCC, with a p-value of 0.001[4]. In their study, the LC density in tumour tissue was compared to that in the overlying or adjacent normal epithelium. In present study, the intratumoural LC density (highlighted by both CD1a and Langerin) were lower in moderate to poorly differentiated group as compared to the well differentiated group. However, this finding was not statistically significant.

## Lymphovascular Invasion (LVI)

Present study analysed the LVI on H&E on all cases. Presence of LVI is associated with a worse prognosis in OSCC. Intratumoural and peritumoural LC density in OSCC was reduced in cases with LVI as compared to those without LVI. However, this association was not statistically significant (p-value >0.05) with both CD1a and Langerin positive cells. In the study by Jardim JF et al., no association was observed between the two parameters [14].

## Perineural Invasion

Perineural invasion is one of the known prognostic indicators of OSCC and is associated with poor outcome. In this study, authors compared the LC density to the perineural invasion status in all the cases. No significant association could be made between the two parameters. Intratumoural and peritumoural LC densities hence have no direct association with perineural invasion. This was in line with the findings in study done by Jardim JF et al., where no

significant association was seen between LC density in OSCC and the presence of perineural invasion [14].

### Tumour Size

In this study, authors examined the association of the tumour size, to the LC distribution. No significant association could be established. Jardim JF et al., in their study, was also unable to establish any direct association between the two parameters [14].

### Depth of Invasion

The depth of invasion was compared with the intratumoural and peritumoural LCs. Present study noted a significant depletion of peritumoural LCs with a depth of invasion of more than 1 cm as compared to those less than 1 cm (p-value of 0.05). A similar association was seen in a study performed by Wei N and Tahan SR, on OSCC of the lip. They noted a depletion in the peritumoural LC with increasing depth of invasion (p-value=0.04) [18].

### Tumour Stage

An elevation in intratumoural CD1a positive LC density was noted with an increase in tumour stage, from T1 to T3 (AJCC staging). This association was significant with a p-value of 0.038. No significant association was established between the T stage and LC distribution in the study by Jardim JF et al., [14].

### Lymph Node Status

In this study, a decreasing peritumoural CD1a positive LC density was seen with increasing nodal stage. The association between the two parameters was statistically significant (p-value: 0.004). In the study by Jardim JF et al., a similar association was noted between Lymph node metastasis and the peritumoural LC density (p-value=0.05). Goldman SA et al., also made a similar observation in their study; with a p-value of 0.01 [19]. In present study, a similar trend was noted in Langerin positive cells. However, no statistical significance was established.

### Limitation(s)

The limited sample size and paucity of poorly differentiated OSCC cases included in the study may pose to be limitations to this study.

### CONCLUSION(S)

A depleted peritumoural density of CD1a positive LC density in OSCC is likely to reflect poor tumour immunity. The use of LC as an independent prognostic indicator of OSCC needs to be

further evaluated. This may, in future, aid the development of immunotherapy triggering LCs in OSCC.

### REFERENCES

- [1] Warnakulasuriya S. Global epidemiology of oral and oropharyngeal cancer. Vol. 45, *Oral Oncology*. Elsevier Ltd; 2009. pp. 309-16.
- [2] Babu KG. Oral cancers in India. *Semin Oncol*. 2001;28(2):169-73.
- [3] Rani SV, Aravindha B, Leena S, Balachander N, Malathi LK, Masthan MK. Role of abnormal Langerhans cells in oral epithelial dysplasia and oral squamous cell carcinoma: A pilot study. *J Nat Sci Biol Med*. 2015;6(Suppl 1):S128-33.
- [4] Lasisi TJ, Oluwasola AO, Lasisi OA, Akang EE. Association between langerhans cells population and histological grade of oral squamous cell carcinoma. *Journal of Oral and Maxillofacial Pathology*. 2013;17(3):329-33.
- [5] Kademani D, Bell RB, Bagheri S, Holmgren E, Dierks E, Potter B, et al. Prognostic factors in intraoral squamous cell carcinoma: The influence of histologic grade. *Journal of Oral and Maxillofacial Surgery*. 2005;63(11):1599-605.
- [6] Shah JP. Cervical lymph node metastases--diagnostic, therapeutic, and prognostic implications. *Oncology (Williston Park)* [Internet]. 1990 Oct 1 [cited 2020 Aug 15];4(10):61-69; discussion 72, 76. Available from: <http://www.ncbi.nlm.nih.gov/pubmed/2149826>
- [7] Warnakulasuriya S. Prognostic and predictive markers for oral squamous cell carcinoma: The importance of clinical, pathological and molecular markers. *Saudi J Med Med Sci*. 2014;2(1):12.
- [8] Woolgar JA, Rogers SN, Lowe D, Brown JS, Vaughan ED. Cervical lymph node metastasis in oral cancer: The importance of even microscopic extracapsular spread. *Oral Oncol*. 2003;39(2):130-37.
- [9] Pentenero M, Gandolfo S, Carozzo M. Importance of tumor thickness and depth of invasion in nodal involvement and prognosis of oral squamous cell carcinoma: A review of the literature. *Head and Neck*. 2005;27:1080-91.
- [10] Rahima B, Shingaki S, Nagata M, Saito C. Prognostic significance of perineural invasion in oral and oropharyngeal carcinoma. *Oral Surg Oral Med Oral Pathol Oral Radiol Endod*. 2004;97(4):423-31.
- [11] The Global Cancer Observatory. Lip, oral cavity- international agency for research on cancer [Internet]. 2020 Available from: <https://gco.iarc.fr/today/data/factsheets/cancers/1-Lip-oral-cavity-fact-sheet.pdf>.
- [12] Sathiyasekar AC, Chandrasekar P, Pakash A, Kumar KUG, Jaishlal MS. Overview of immunology of oral squamous cell carcinoma. *Journal of Pharmacy and Bioallied Sciences*. Medknow Publications; 2016;8:S8-12.
- [13] Curado MP, Johnson NW, Kerr AR, Silva DRM e, Lanfranchi H, Pereira DL, et al. Oral and oropharynx cancer in South America. *Translational Research in Oral Oncology* [Internet]. 2016 Aug 3 [cited 2020 Jul 19];1:2057178X1665376.
- [14] Jardim JF, Gondak R, Galvis MM, Pinto CAL, Kowalski LP. A decreased peritumoural CD1a+cell number predicts a worse prognosis in oral squamous cell carcinoma. *Histopathology*. 2018;72(6):905-13.
- [15] Mizumoto N, Takashima A. CD1a and langerin: Acting as more than Langerhans cell markers. *J Clin Invest*. 2004;113(5):658-60.
- [16] College of American Pathologists. Protocol for the examination of specimens from patients with cancers of the lip and oral cavity. 2017 [cited 2023 Jan 24]; Available from: [www.cap.org/cancerprotocols](http://www.cap.org/cancerprotocols).
- [17] Amin MB et al. (Eds. ). *AJCC Cancer Staging Manual* (8th edition). 2018.
- [18] Wei N, Tahan SR. S100+cell response to squamous cell carcinoma of the lip: Inverse correlation with metastasis. *J Cutan Pathol*. 1998;25(9):463-68.
- [19] Goldman SA, Baker E, Weyant RJ, Clarke MR, Myers JN, Lotze MT. Peritumoural CD1a-positive dendritic cells are associated with improved survival in patients with tongue carcinoma. *Archives of Otolaryngology-Head and Neck Surgery* [Internet]. 1998 [cited 2020 Sep 26];124(6):641-46.

#### PARTICULARS OF CONTRIBUTORS:

1. Assistant Professor, Department of Pathology, MES Medical College, Palachode, Perinthalmanna, Kerala, India.
2. Professor, Department of Pathology, Amala Institute of Medical Sciences, Thrissur, Kerala, India.
3. Associate Professor, Department of Pathology, Amala Institute of Medical Sciences, Thrissur, Kerala, India.

#### NAME, ADDRESS, E-MAIL ID OF THE CORRESPONDING AUTHOR:

Dr. Sandhra Usman,  
Assistant Professor, Department of Pathology, MES Medical College,  
Perinthalmanna -679321, Kerala, India.  
E-mail: [snu.usman@gmail.com](mailto:snu.usman@gmail.com)

#### PLAGIARISM CHECKING METHODS: [Jain H et al.]

- Plagiarism X-checker: Nov 21, 2022
- Manual Googling: Feb 22, 2023
- iThenticate Software: Mar 07, 2023 (6%)

#### ETYMOLOGY: Author Origin

#### AUTHOR DECLARATION:

- Financial or Other Competing Interests: None
- Was Ethics Committee Approval obtained for this study? Yes
- Was informed consent obtained from the subjects involved in the study? Yes
- For any images presented appropriate consent has been obtained from the subjects. Yes

Date of Submission: **Nov 16, 2022**

Date of Peer Review: **Jan 19, 2023**

Date of Acceptance: **Apr 03, 2023**

Date of Publishing: **May 01, 2023**