



Compressive Lipoma of the Hand Causing Carpal Tunnel Syndrome

Sbai Mohamed Ali ^a, Ben Omrane Youssef ^{a*}, Ben Othma Nadia ^b,
Trabelsi Becem ^c, Mecheel Ben Ali ^c and Bouzaidi Khaled ^b

^a Department of Plastic, Reconstructive and Burns Surgery CHU Nabeul, Faculty of Medicine of Tunis, University El Manar Tunis Tunisia, Tunisia.

^b Service of radiology CHU Nabeul, Faculty of Medicine of Tunis, University El Manar Tunis Tunisia, Tunisia.

^c Service of anesthesia resuscitation CHU Nabeul, Faculty of Medicine of Tunis, University El Manar Tunis Tunisia, Tunisia.

Authors' contributions

This work was carried out in collaboration among all authors. Author MAS and TB Data collection Author MAS, Ben OY Drafting of the article. Author BON 'MBA, BK Revision of article. All authors read and approved the final manuscript.

Article Information

Open Peer Review History:

This journal follows the Advanced Open Peer Review policy. Identity of the Reviewers, Editor(s) and additional Reviewers, peer review comments, different versions of the manuscript, comments of the editors, etc are available here: <https://www.sdiarticle5.com/review-history/85505>

Received 15 November 2021

Accepted 19 January 2022

Published 20 January 2022

Case Study

ABSTRACT

Aims: We report the case of a patient presenting with paresthesia in the median nerve territory following compression by a palmar lipoma evoking a carpal tunnel syndrome. The aim of this work is to review the epidemiological, diagnostic and therapeutic aspects of this pathology.

Presentation of Case: We present the case of a 40-year-old female patient who presented paresthesia in the territory of the median nerve, the clinical and paraclinical examinations showed the presence of a lipoma of the middle palmar region of the right hand at the origin of a compression of the branches of division of the median nerve; The resection of the lipoma and the neurolysis of the interdigital nerves of the median nerve have allowed a good evolution

Discussion: Lipoma of the hand is a very rare localization that can lead to nerve compression and can mimic the symptoms of carpal tunnel. The diagnosis is facilitated by ultrasound and magnetic resonance imaging (MRI).

Conclusion: Compression of the median nerve by a lipoma is a very rare cause. The removal of the lipoma and the neurolysis of the median nerve gives excellent results.

Keywords: Carpal tunnel syndrome; lipoma; hand.

1. INTRODUCTION

“Carpal tunnel syndrome is the most frequently encountered peripheral compressive neuropathy, causing pain, numbness and tingling in the upper extremity. In the majority of cases carpal tunnel syndrome is idiopathic in origin, in 20% of cases it is a secondary cause following a systemic disease, including rheumatoid arthritis, hypothyroidism, diabetes mellitus, acromegaly, pregnancy and chronic renal failure. Carpal tunnel syndrome caused by extrinsic compression (synovial cyst or lipoma) is exceptional. Lipomas are the most common benign tumors of the extremities” [1]. “Although the occurrence of lipomas of the hand remains rare, between 1 and 3.8% of benign tumors of the hand” [2]. “Compression of the median nerve by a lipoma is very rare and leads to an atypical clinical presentation that may mimic carpal tunnel syndrome” [3]. The diagnosis is facilitated by radiological explorations (ultrasound and MRI). We present a case of carpal tunnel syndrome caused by compression by a lipoma. The objective of this work is to see the epidemiological, diagnostic and therapeutic aspects of this rare etiology of carpal tunnel syndrome.

2. PRESENTATION OF CASE

A 40-year-old woman, right-handed, a laborer (hairdresser) with no notable pathological history, presented with numbness, tingling, pain and

weakness of the right hand evolving for 1 year, without any notion of trauma.

The interrogation of the patient revealed a progressive evolution over several months with a progressive Acro paresthesia of the median nerve territory associated with palmar pain. Physical examination revealed a decrease in epicritic sensitivity with the Weber test, without any sign of motor disorder, associated with a soft middle palmar swelling of the right hand, fixed in relation to the deep plane (Fig. 1).

Functional exploration by electromyography showed a decrease in the conduction velocity of the median nerve at the wrist and concluded to a sensory carpal tunnel syndrome. Standard radiographs found no abnormalities. Ultrasound of the right hand showed a homogeneous iso echogenic fusiform formation measuring 32 by 13 mm non vascularized, compressing the deep and superficial flexors of the Medius and the median nerve after its division (Fig. 2). MRI showed the presence of a subcutaneous mass opposite the palmar surface of the third metacarpal, oval, well limited, measuring 12x13x27 mm, in homogeneous T1 and T2 hypersignal with a drop in signal after saturation of the fat, not enhanced after injection of gadolinium, it contains a few trabeculae in T2 hypo signal, this mass inuncts between the deep flexor of the right Medius and ring finger and compresses the nerve after its division (Fig. 3).

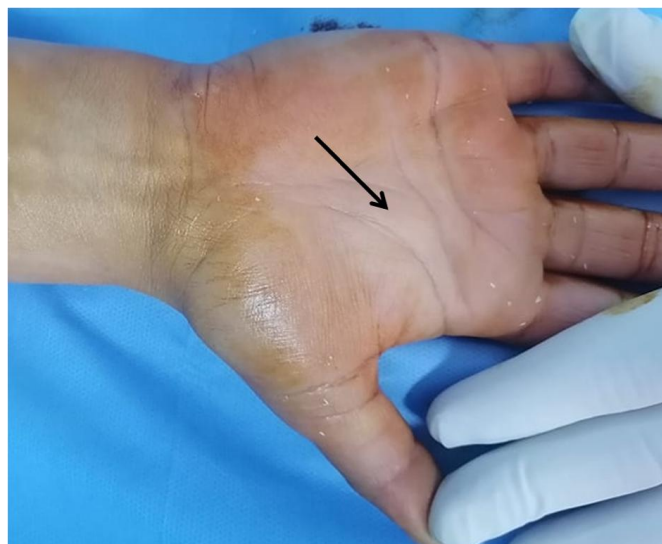

Fig. 1. Pre- operative photo showing palmar swelling of the right hand

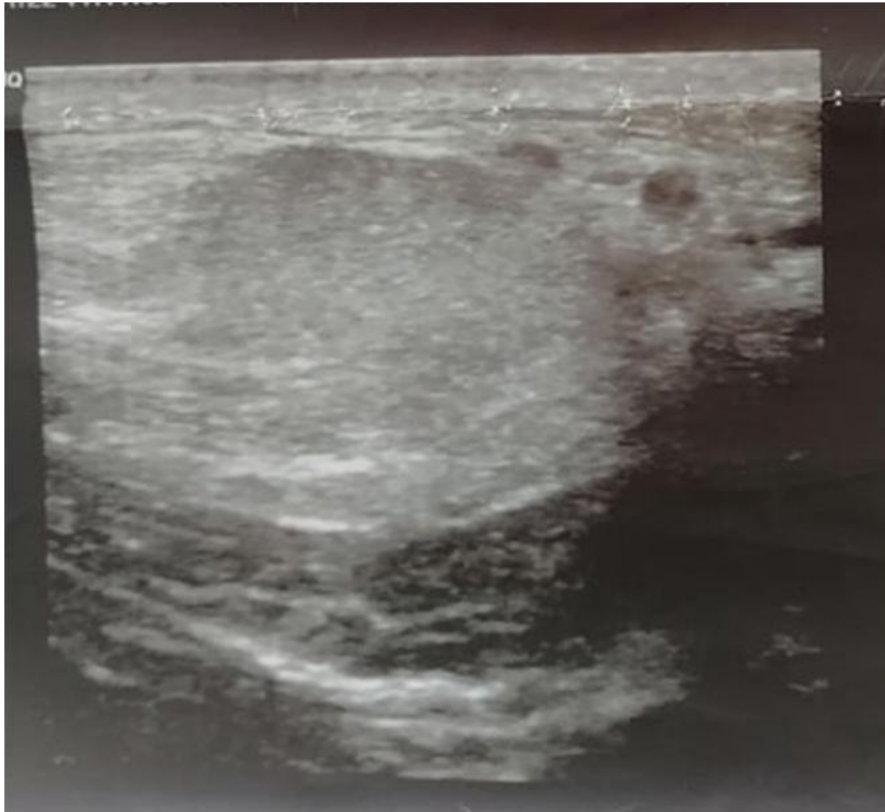

Fig. 2. Ultrasound image of the right hand showing the fusiform mass compressing the deep and superficial flexors of the medius and ring finger and median nerve

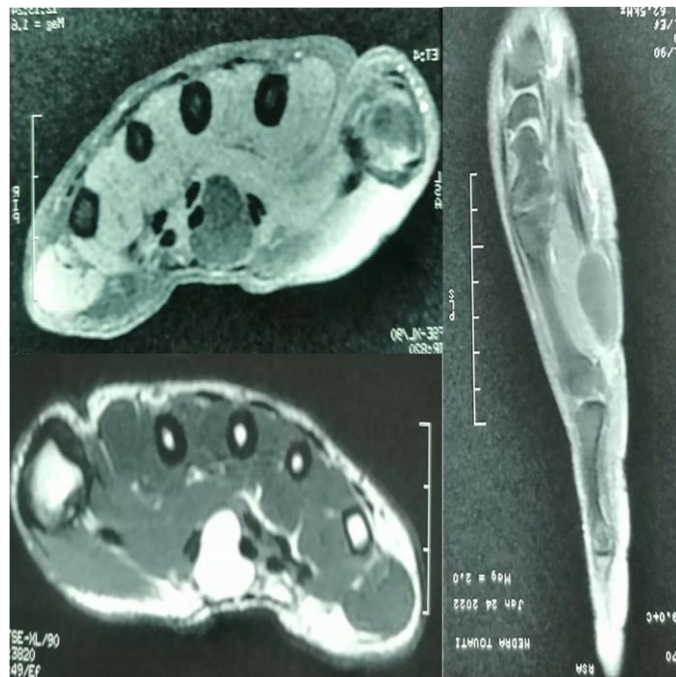


Fig. 3. MRI images showing the tumor in homogeneous T1 and T2 hypersignal (red arrows)

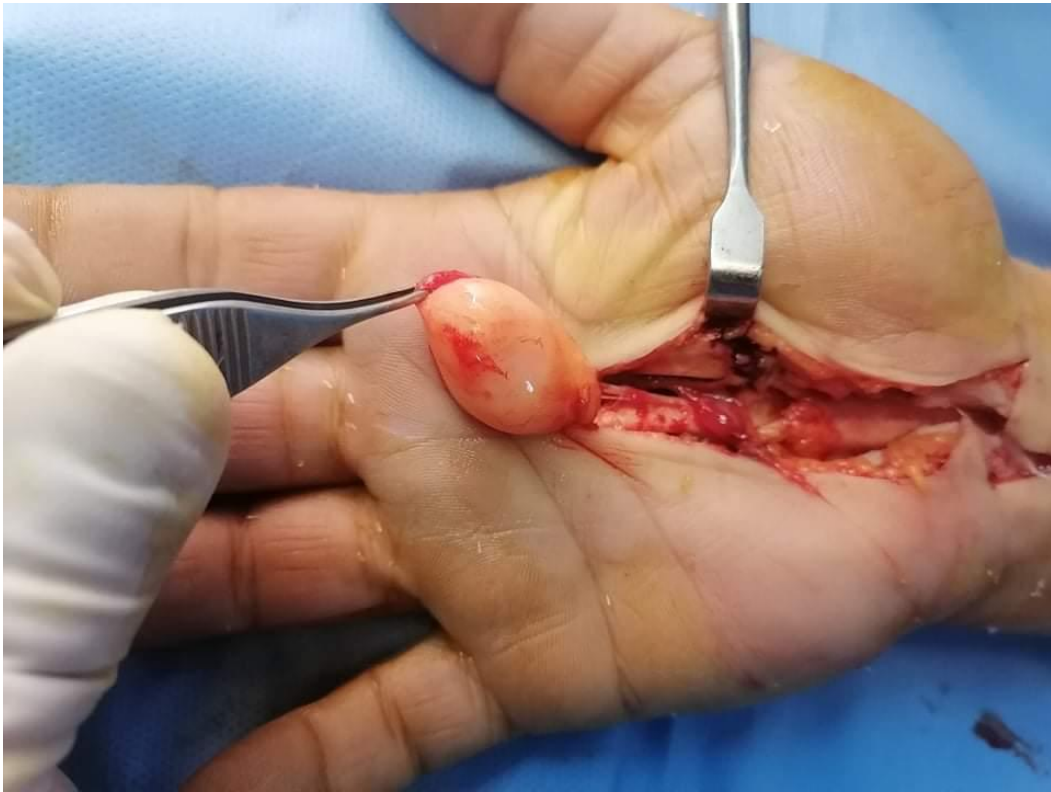

Fig. 4. Intra operative picture showing the conventional incision of carpal tunnel syndrome Extended to the palm and the resected tumor

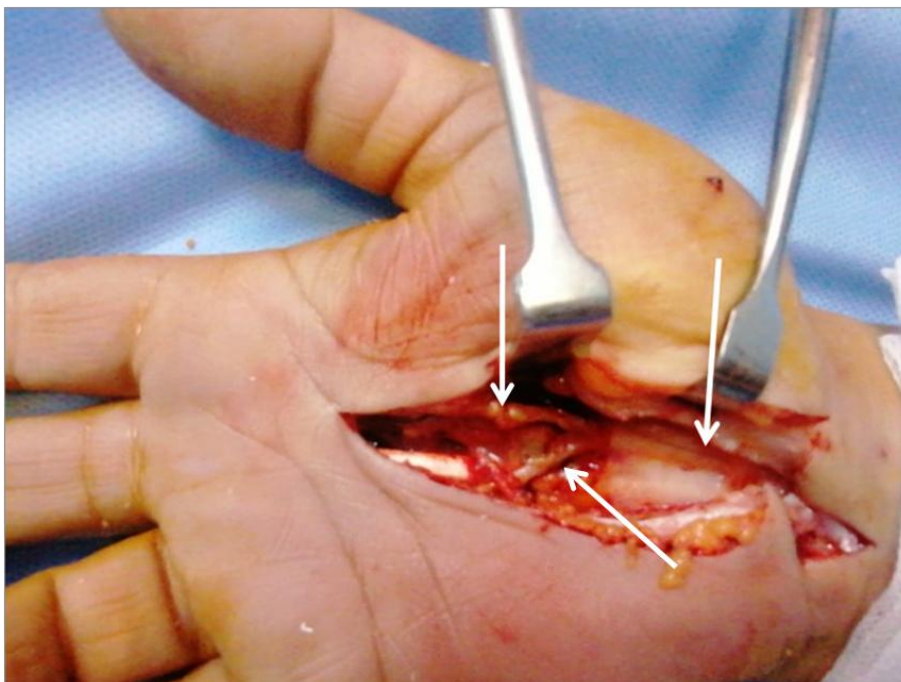


Fig. 5. Intra operative picture after neurolysis with median nerve (right arrow) And its branches to 2nd (left arrow) and 3rd (middle arrow) branches

We performed a surgical resection of the tumor under locoregional anesthesia with a conventional approach to the carpal tunnel and extended to the midpalmar region (Fig. 4). The resection of the lipoma was easy. We performed a neurolysis of the median nerve and its dividing branches (interdigital nerve of the 2nd, 3rd and 4th space) (Fig. 5). The evolution was good, with disappearance of paresthesia on the first day postoperatively and a return to work after 45 days, including one month of rehabilitation. Anatomopathological examination confirmed the diagnosis of lipoma.

3. DISCUSSION

“Carpal tunnel syndrome is known to be of idiopathic origin in most cases, the secondary origin remains a rare etiology represented by chronic renal failure, systemic diseases, pregnancy, diabetes, dysthyroidism, extrinsic compression by a tumor such as a synovial cyst or a lipoma remains a rare etiology Lipomas represent 16% of all mesenchymal tumors” [4]. “Although they are mostly located in the lower limbs, their location in the hand is rare and particularly interesting because of their atypical expression. However, lipoma is an exceptional cause of CTS, few cases have been reported in the literature” [3,4,5,6,7,8,9,10,11], Chen found 3 lipomas among 23 cases of extrinsic tumor compression in 779 CTS patients [12], Ho Jung Kang did not report any case of compression by a lipoma in a series of 568 CTS cases [13]. Elbardouni reports a case of CTS caused by a lipoma in 13 patients with confirmed deep lipomas of the upper extremity [14].

The diagnosis of carpal tunnel syndrome is made clinically in the presence of paresthesia in the median nerve territory, in the presence of positive provocation tests (Phalen's test) and in the search for a pseudotinal nerve. The suspicion of an extrinsic compression is evoked by the existence of a swelling on the anterior aspect of the wrist or the palmar aspect of the hand. Electromyographic study of the median nerve can confirm the diagnosis of carpal tunnel syndrome by showing a slowing of the nerve conduction velocity or a conduction block but without information on the etiology of CTS.

“Ultrasound is a simple, innocuous, available, and repeatable examination and is of great interest in the etiological assessment of CTS. Ultrasound provides a view of the anatomy of the nerve as well as the surrounding structures and

allows for a real-time, painless assessment of median nerve compression. Typical findings associated with nerve compression include enlargement of the nerve proximal to the site of compression, decreased echogenicity, and increased vascularity” [15]. “In addition, ultrasound allows accurate differentiation of lesions occupying the space causing median nerve compression” [12]. Lipomas are typically elongated lesions with the biggest diameter parallel to the skin and an anterior-posterior length-to-diameter ratio of about 3:1. A homogenous hyperechoic structure with well-defined boundaries and no posterior enhancement or colour Doppler signal is typical of the lesion.

“MRI is the visualization modality of choice for the exploration of hand tumors. First, it allows diagnostic orientation of the tumor, and second, it shows the anatomical relationships between the tumor and neurovascular structures. Classically, lipomas present as a homogeneous mass, with a sharp contour, spontaneous T1 and T2 hypersignals, decreased signal intensity after erasure of the fatty signal, and no signal elevation with gadolinium contrast” [16, 17]. “Thin sections, less than 2 mm, allow identification of septae within the tumor, which appear small, discretely raised features after gadolinium injection [16]. In a review of 134 cases of hand and wrist tumors, Capelastegui compared MRI scans with histologic findings. He concluded that MRI has a positive predictive value, close to 94%” [1].

“The differential diagnosis of this type of tumor includes mainly median nerve fibro lipoma and low-grade liposarcoma. Median nerve fibro lipoma represents only 2% of soft tissue tumors” [18]. “On MRI, it appears as a well-differentiated mass with a sharp border and a heterogeneous signal consisting of a mixed composition of fat and fibrosis. A pathognomonic sign of this disease is the swelling of the fatty signal crossed by low signal nerve fibers” [19]. “It is a benign tumor that develops from fibroblasts and adipocytes of the epineurium. It always remains purely intraneural” [20]. Resection frequently fails to disassociate the tumour from the usual nerve fibres, making therapeutic care problematic.

“Rarely, other differential diagnoses occur and could be another soft tissue tumor, such as a ganglion cyst or a giant cell tumor” [12].

“Therapeutically, conventional release of the carpal tunnel and removal of the lipoma resulted in immediate indolence. Surgical resection of lipomas is the only treatment that can release the compressed nerve . Some authors state that the risk of recurrence is correlated to the degree of heterogeneity found on the first MRI examination” [8].

4. CONCLUSION

Lipomas are rarely observed in the hand and wrist, but lipoma as a cause of secondary carpal tunnel syndrome is even rarer, The diagnosis is clinical, functional exploration by electromyography is essential for authentication of the level of compression, ultrasound is an indispensable examination in the etiological assessment of carpal tunnel syndrome. In terms of predictive values, MRI is the best morphological examination for exploring malignancies of the hand and wrist. Surgery is the treatment of choice for these lesions since it provides for a quick functional recovery. Because to the intimate proximity of the lipoma and the nerve, the greatest risk of iatrogenic injuries during surgical excision remains.

CONSENT

As per international standard or university standard, patients' written consent has been collected and preserved by the author(s).

ETHICAL APPROVAL

As per international standard or university standard written ethical approval has been collected and preserved by the author(s).

COMPETING INTERESTS

Authors have declared that no competing interests exist.

REFERENCES

1. Capelastegui A, Astigarraga E, Fernandez-Canton G, Saralegui I, Larena JA, Merino A, “Masses and pseudomasses of the hand and wrist: MR findings in 134 cases,” *Skeletal Radiology*. 1999;28(9):498–507.
2. Amar FM, Benjelloun H, Ammoumri O, Marzouki A, Mernissi FZ, Boutayeb F. “Lipome compressif de la tabatiere anatomique. A propos d'un cas,” *Annales*

- de Chirurgie Plastique et Esthétique. 2010 ;57:409–411.
3. Fnini S, Hassoune J, Garche A, Rahmi M, Largab A. “Giant lipoma of the hand: case report and literature review,” *Chirurgie de la Main*. 2010; 29(1):44–47.
4. Kremchek TE, Kremchek EJ. Carpal tunnel syndrome caused by flexor tendon sheath lipoma. *Orthop Rev*. 1988;17:1083–1085.
5. Pagonis T, Givissis P, Christodoulou A. “Complications arising from a misdiagnosed giant lipoma of the hand and palm: a case report,” *Journal of Medical Case Reports*. 2011;5,article 552.
6. Nakamichi K, Tachibana S. Unilateral carpal tunnel syndrome and space-occupying lesions. *J Hand Surg [Br]* 1993;18:48–49.
7. Bagatur AE, Yalcinkaya M. Unilateral carpal tunnel syndrome caused by an occult palmar lipoma. *Orthopedics*. 2009 ; 32(10).
8. Jalan D, Garg B, Marimuthu K, Kotwal P. Giant lipoma: an unusual cause of carpal tunnel syndrome. *Pan Afr Med J*. 2011;9:29.
9. AbdelghaniMenadi. Lipome compressif de la région palmaire de la main droite – à propos d'un cas *Hand Surgery and Rehabilitation*. 2017;36(6): 477-478.
10. Belle Tellier 1, Mariam Gabrian 2, Jean-Bart Jaquet . Carpal tunnel syndrome caused by a giant lipoma of the hand: A case report. 2021;80:105647.
11. Barreira M, Marques N, Campos V, Marques G, Gonçalves S, Stefanova Alves S. A giant hand lipoma as a rare cause of secondary carpal tunnel syndrome - A case report. *Int J Surg Case Rep*. 2020;77:538-542.
12. Chen C H, Wu T, Sun J S, Lin W H, Chen C Y. Unusual causes of carpal tunnel syndrome: space occupying lesions. *J Hand Surg Eur*. 2012; 37(1): 14-19.
13. Ho Jung Kang, Sung Hoon Jung, Hong Ki Yoon, Soo Bong Hahn, and Sung Jae Kim. Carpal Tunnel Syndrome Caused by Space Occupying Lesions. *Yonsei Med J*. 2009; 50(2): 257-261.
14. A. Elbardouni, M. Kharmaz, M. Salah Berrada, M. Mahfoud, M. Elyaacoubi. Well-circumscribed deep-seated lipomas of the upper extremity. A report of 13 cases. *Orthopaedics & Traumatology: Surgery & Research*. 2011; 97(2):152–158.
15. Suk JL, Walker FO, Cartwright MS. “Ultrasonography of peripheral nerves,”

- Current Neurology and Neuroscience Reports. 2013;13(2):328.
16. Ergun T, Lakadamyali H, Derincek A, Cagla Tarhan N, Ozturk A. "Magnetic resonance imaging in the visualization of benign tumors and tumor-like lesions of hand and wrist," Current Problems in Diagnostic Radiology. 2010;39(1):1–16.
 17. Goodwin RW, P. O'Donnell, Saifuddin A, "MRI appearances of common benign soft-tissue tumours," Clinical Radiology. 2007; 62(9):843–853.
 18. Kossoko H, Allah CK, Richard Kadio M, Yéo S, Assi-Djè Bi Djè V, Gueu M. "Fibrolipoma of the median nerve. A case report," Chirurgie de la Main. 200 ;27(6):269–271.
 19. Cavallaro MC, Taylor JAM, Gorman JD, Haghighi P, Resnick D. "Imaging findings in a patient with fibrolipomatous hamartoma of the median nerve," American Journal of Roentgenology. 1993; 161(4):837–838.
 20. Chick G, Alnot JY, Silbermann-Hoffman O. "Tumeurs bénignes isolées des nerfs périphériques,"Revue de Chirurgie Orthopédique et Réparatrice de l'Appareil Moteur. 2000;86(8):825–834.

© 2022 Ali et al.; This is an Open Access article distributed under the terms of the Creative Commons Attribution License (<http://creativecommons.org/licenses/by/4.0>), which permits unrestricted use, distribution, and reproduction in any medium, provided the original work is properly cited.

Peer-review history:

The peer review history for this paper can be accessed here:
<https://www.sdiarticle5.com/review-history/85505>