

## **Bilateral Thrombophilia Discovered in a Young Child Misdiagnosed Initially with Osteoarthritis**

**P. M. Mulendelé<sup>a</sup>, M. Njie<sup>a\*</sup>, B. E. Ovaga<sup>a</sup>, M. Haboub<sup>b</sup>, A. Arous<sup>b</sup>,  
Med G. Benouna<sup>a,b</sup>, A. Drighil<sup>a,b</sup>, L. Azzouzi<sup>a,b</sup> and R. Habbal<sup>a,b</sup>**

<sup>a</sup> Department of Cardiology P37, Ibn Rochd University Hospital, Casablanca, Morocco.

<sup>b</sup> Faculty of Medicine and Pharmacy, Hassan II university of Casablanca, Casablanca, Morocco.

### **Authors' contributions**

*This work was carried out in collaboration among all authors. All authors read and approved the final manuscript.*

### **Article Information**

#### **Open Peer Review History:**

This journal follows the Advanced Open Peer Review policy. Identity of the Reviewers, Editor(s) and additional Reviewers, peer review comments, different versions of the manuscript, comments of the editors, etc are available here: <https://www.sdiarticle5.com/review-history/90578>

**Case Study**

**Received 01 June 2022**  
**Accepted 07 August 2022**  
**Published 11 August 2022**

## **ABSTRACT**

**Introduction:** The occurrence of venous thrombosis in children is rare, often idiopathic and rarely a known etiology can be found, with sometimes a delay diagnostic in most cases.

**Method:** We report a case illustrating the difficulties of diagnosing phlebitis and a fairly rare etiology in an 11-year-old boy: the diagnosis of venous thrombosis on thrombophilia was made 12 days after the onset of pain in both lower limbs after an initial diagnosis of osteoarthritis or acute synovitis of the hip.

**Conclusion:** The diagnosis of thrombo-phlebitis should be considered in the presence of any persistent unexplained pain in a limb in children. Early diagnosis and effective anticoagulation are essential for the prevention of post-phlebotic syndrome.

*Keywords: Deep vein thrombosis; antithrombin deficiency; vitamin K antagonist (VKA).*

## **1. INTRODUCTION**

Venous thromboembolic disease in childhood is a multifactorial disease. Risk factors include acquired clinical risk factors such as a central

venous catheter and underlying disease and inherited thrombophilia [1]. Inherited thrombophilia is defined as a genetically determined tendency to develop venous thromboembolism. The contributing role of

\*Corresponding author: E-mail: malick1njie@hotmail.com;

inherited thrombophilia is not clear in many pediatric thrombotic events, especially catheter-related thrombosis. Furthermore, identification of inherited thrombophilia will not often influence acute management of the thrombotic event as well as the duration of anticoagulation. In some patients, however, detection of inherited thrombophilia may lead to identification of other family members who can be counseled for their thrombotic risk [2,3]. The present study aimed to discuss the bilateral thrombophilia discovered in a young child misdiagnosed initially with osteoarthritis.

## 2. CASE REPORT

An 11-year-old boy, with no medical history, has notion of consanguinity, presented at the pediatric emergency department with spontaneous pain in the left thigh of progressive worsening for 9 days in a context of hyperthermia raising the suspicion of osteoarthritis or an acute synovitis of the left hip.

The ultrasound of the left hip, the radiography and the computed tomography scan (CT-scan) of the pelvis were normal.

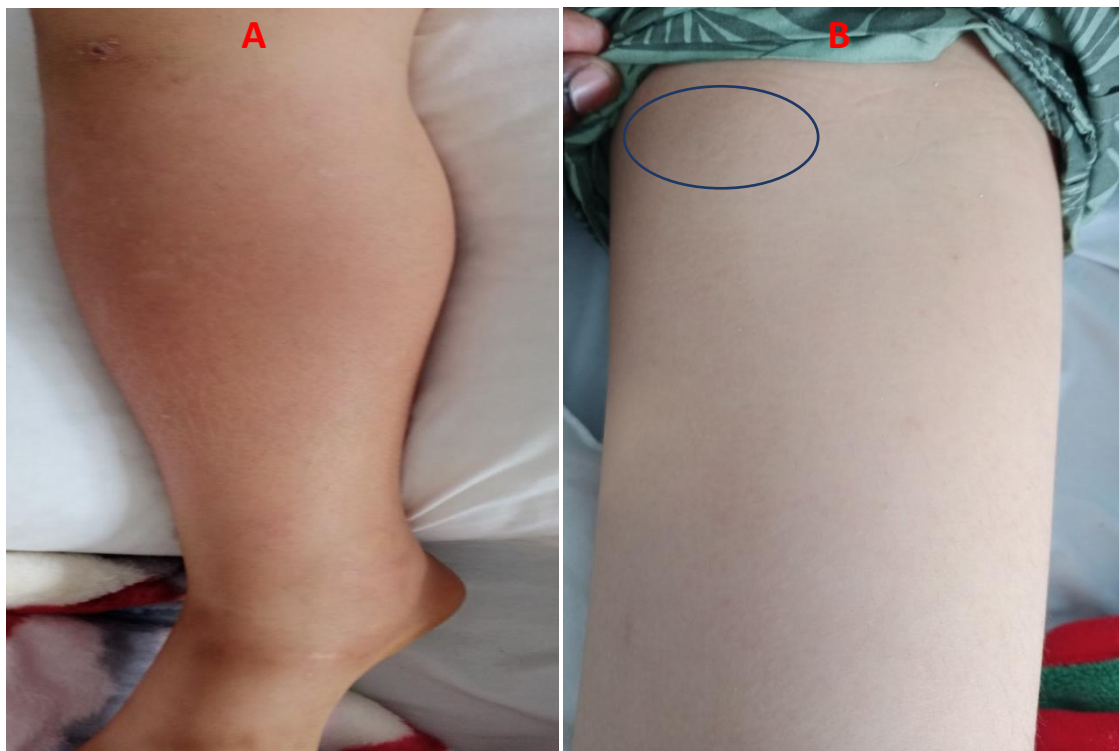
The blood count noted hyperleukocytosis at 16,260/ $\mu$ l with neutrophilia predominance at 12,330/ $\mu$ l, an hemoglobin level of 11.7 g/dl; a platelet count at 259,000/ $\mu$ l; C-reactive protein at 300mg/dl, an early sedimentation rate (ESR) at the first hour at 32; D-dimers enzymes at 216ng/ml.

The child was hospitalized (on Day12) due to the persistence of pain in the left hip and the appearance of swelling in the right leg.

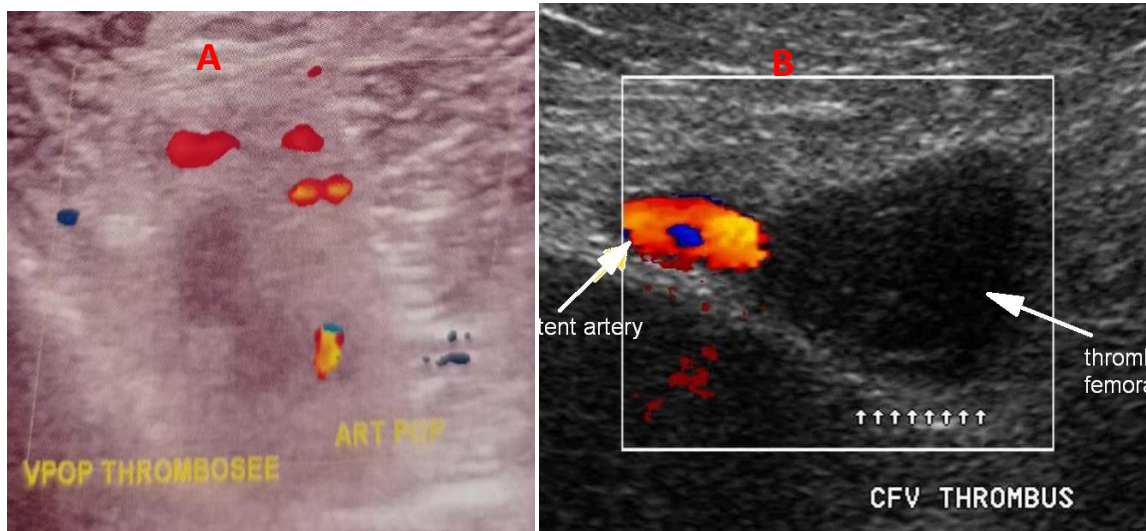
On physical examination, we noted: a painful swelling of the right leg extending from the knee to the ankle, with inflammatory signs; the Homan's sign was positive with a decrease in the sloshing of the right calf, pain at the root of the left thigh and mobilization of the pelvis (Fig. 1).

The complete blood count and hemostasis assessment were normal apart from elevated D-dimers at 1640ng/ml.

The venous Doppler ultrasonography concluded with the diagnosis of a deep vein thrombosis (DVT) at the level of the left common femoral vein and the right popliteal vein (Fig. 2).



**Fig. 1. A- A photo showing a swelling, inflamed right leg extending from the knee to the ankle  
B- A photo showing painful region of the left thigh with inflammatory signs (blue circle)**



**Fig. 2. A-Doppler ultrasonography of the right lower limb: showing a deep vein thrombosis (DVT) of the right popliteal vein**  
**B-Doppler ultrasonography of the left lower limb: showing a DVT of the left common femoral vein**

The electrocardiogram, echocardiography, abdominopelvic ultrasound and chest CT angiography were normal.

The search for thrombophilia, despite the absence of a family history, revealed an antithrombin deficiency (anti-IIa cofactor activity at 50% for a normal between 80% and 125%, antigen at 0.16 g/l for a normal between 0.22 and 0.3 g/l), associated with a heterozygous mutation of factor V of Leiden type. The study of C -protein and S -protein was normal; as well as the research for an antiphospholipid syndrome (APLS) after specified antibodies dosage.

The family investigation found an antithrombin deficiency in the mother and a factor V mutation in the father.

Treatment consists of low molecular weight heparin (LMWH example: Lovenox) at a curative dose of 100UI/kg/12h with combined supplementation of Aclotine at a dose of 42.8UI/kg/24h from Day14 with bed rest and compression stockings.

A vitamin K antagonist (VKA) therapy relay was started 4 days later with a switch treatment to Aclotine every other day.

Aclotine supplementation was stopped after 10 days and heparin therapy after 12 days.

We observed a clinical improvement from the 3rd day of hospitalization with regression of symptoms.

The evolution at 2 months was marked by the absence of post-phlebitis syndrome. VKA therapy was indicated as a long preventive therapy for thrombosis in this patient.

#### 4. DISCUSSION

Our case report highlights the difficulty of diagnosing venous thrombosis in children and the presence of constitutional and/or acquired factors predisposing to thrombosis. The incidence of thrombophlebitis and pulmonary embolism is significantly lower in children than that in adults, estimated at 0.06 to 0.07/10,000 children per year in a Canadian study, while it is approximately 2 to 7 /10,000 patients per year in adults [4,5]; however, it is increasing [6], with two frequency peaks observed: one before the age of one year corresponding mainly to thrombosis on the catheter and the other after the age of 11 years coinciding with puberty [4,5]. Several mechanisms are likely contributive to the protective effect of age for venous thromboembolism (VTE). These include reduced ability to generate thrombin [7,8], increased ability of  $\alpha 2$  macroglobulin to inhibit thrombin [9], and increased antithrombotic potential by the vessel wall [10]. However, an increasing number of children are developing VTE as secondary complications of their underlying disorders; one

or more predisposing factors, acquired or congenital, are found in more than 95% of childhood thrombosis [1,2] such as cancer, trauma/surgery, congenital heart disease and systemic lupus erythematosus (SLE) [11,12,13] and congenital prothrombotic states [14], as in our case.

Pain is often prominent, and may be associated with swelling, redness or discoloration of the skin, decreased passive calf sway, and possible signs of pulmonary embolism [2,15]. The frequency of asymptomatic deep vein thrombosis diagnosed during systematic radiological explorations should be emphasized [16]. However, the diagnosis of phlebitis is often evoked late in children because of its rarity. The location of the pain and the possible presence of a fever and an inflammatory syndrome may lead to initially evoke erroneous diagnosis such as an osteoarticular infection, as in our case, if a bilateral location may raise suspicion of a neoplastic process [17], we did not find such a description in the literature concerning thrombophilia.

The diagnosis of venous thrombosis of a limb is based on the venous Doppler ultrasonography which must be carried out easily at the slightest diagnostic doubt; the sensitivity of this examination is 95% and its specificity 96%. The early dosage of D-dimers has a negative predictive value. In case of diagnostic doubt, other minimal invasive imaging techniques can also be used: CT scan with injection; magnetic resonance angiography; helical CT angiography. Venography is currently hardly used anymore [18]. The speed of diagnosis is an essential element for the prevention of early complications, dominated by the extension of thrombosis with possible occurrence of pulmonary embolism, and late complications, dominated by postphlebotic syndrome, present in 12.4% of children according to the Canadian registry [19].

This syndrome can occur five to ten years after the thrombosis. It persists for life, and its frequency of occurrence is greater when the diagnosis of phlebitis is late, and the time it takes to obtain effective anticoagulation is long [1]. In our case, the diagnosis was late but the obtaining of an effective anticoagulation was early, which probably made it possible to avoid the constitution of a post-phlebotic syndrome.

The occurrence of apparently isolated and moreover bilateral venous thrombosis therefore requires the search for constitutional and acquired thrombogenic factors. The search for a neoplastic process, but also for constitutional thrombogenic factors must be systematic, and includes: the search for a Q506 mutation of factor V (factor V Leiden type), and G20210 A of factor II, the dosage of proteins C and S, antithrombin, homocysteine, lipoprotein 'a' [7,15].

Some laboratory analyses abnormalities could be associated with an increased risk thrombosis in numerous acquired pathologies: presence of antiphospholipid and anti-cardiolipid antibodies, systemic inflammatory diseases (systemic lupus erythematosus, inflammatory diseases of the digestive tract, Behçet's disease), nephrotic syndrome, malignant pathologies, bacterial or viral infections (transient acquired deficiencies in protein C and S of autoimmune origin, mainly described during chickenpox), drug intake (oral contraceptives in adolescents) [7,3]. Certain genetic diseases are also associated with an increased risk of thrombosis: sickle cell disease, certain metabolic diseases (homocysteinuria, protein glycosylation deficiency [Congenital Disorders of glycosylation-CDG syndrome]). The association with other predisposing factors linked to the clinical context is frequent: thrombosis on a central catheter, which represent 25 to 33% of cases of thrombosis at pediatric age [4,20,21,2], local factors (immobilization in plaster, prolonged bed rest, surgery, nearby bone or ear-nose-tongue (ENT) infection, venous malformation) In this reported case, the presence of two factors predisposing to thrombosis was found: antithrombin deficiency and the presence of a heterozygous mutation of factor V of the Leiden type.

## 5. CONCLUSION

The diagnosis of phlebitis must therefore be considered in the presence persistent unexplained pain in a limb in children, and thrombophilia even in the event of bilateral localization. Early diagnosis and rapid initiation of effective anticoagulation are essential to prevent the occurrence of post-phlebotic syndrome.

## CONSENT

As per international standard, parental written consent has been collected and preserved by the author(s).



## ETHICAL APPROVAL

It is not applicable

## COMPETING INTERESTS

Authors have declared that no competing interests exist.

## REFERENCES

1. Van Ommen CH, Nowak-Göttl U. Inherited thrombophilia in pediatric venous thromboembolic disease: why and who to test. *Frontiers in Pediatrics*. 2017;5:50.
2. Cohn DM, Roshani S, Middeldorp S. Thrombophilia and venous thromboembolism: implications for testing. *Semin Thromb Hemost*. 2007;33:573–81.
3. Griffin JH, Evatt B, Zimmerman TS, Kleiss AJ, Wideman C. Deficiency of protein C in congenital thrombotic disease. *J Clin Invest*. 1981;68:1370.
4. Andrew M, David M, Adams M, Ali K, Anderson R, Barnard D, et al. Venous thromboembolic complications (VTE) in children: first analyses of the Canadian registry of VTE. *Blood* 1994;83:1251–7.
5. Revel-Vilk S, Chan AK, Bauman M, Massicotte MP. Troubles prothrombotiques dans une cohorte non sélectionnée d'enfants atteints d'une maladie thromboembolique veineuse. *J Thromb Haemost*. 2003;1:915-21.
6. Spentzouris G, Scriven RJ, Lee TK. Pediatric venous Thromboembolism in relation to adults *Journal of vascular surgery* 2012;55:1785-1793.
7. Bader-Meunier B, Proulle V, Pariente D, Dreyfus M, Dommergues JP. Thromboses veineuses de l'enfant, Journées parisiennes de pédiatrie 2000. Flammarion médecine–sciences Paris. 2000:161–8.
8. Andrew M, Schmidt B, Mitchell L, Paes B, Ofosu F. La génération de thrombine dans le plasma du nouveau-né dépend essentiellement de la concentration de prothrombine. *Thromb Haemost* 1990;63:27-30.
9. Andrew M, Mitchell L, Vegh P, Ofosu F. L régulation de la thrombine chez les enfants diffère de celle des adultes en l'absence et en la présence d'héparine. *Thromb Haemost* 1994;2: 836-42.
10. Ling X, Delorme M, Berry L, Ofosu F, Mitchell L, Paes B, Andrew M. L'alpha 2-macroglobuline reste aussi importante que l'antithrombine III pour la régulation de la thrombine dans le plasma du cordon en présence de surfaces de cellules endothéliales. *Pediatr Res*. 1995; 37:373-8.
11. Xu L, Delorme M, Berry L, Brooker L, Mitchell L, Andrew M. Génération de thrombine dans le plasma du nouveau-né et de l'adulte en présence d'une surface endothéliale. *Thromb Haemost*. 1991 ;65:1230.
12. Andrew M, David M, Adams M. Complications thromboemboliques veineuses (TEV) chez les enfants : premières analyses du Registre canadien des TEV. *Sang* 1994;83:125 1-7.
13. Berude C, Mitchell L, Silverman E, David M, Saint CC, Laxer R, Adams M, Vegh P, Andrew M. La relation entre les anticorps anti phospholipides et les événements thromboemboliques chez les patients pédiatriques atteints de lupus érythémateux disséminé : une étude transversale. *Pediatr Res* 1998;44: 351-6.
14. Schmidt B, Andrew M. Thrombose neonatal. Rapport d'un registre prospectif canadien et internationale *Pédiatrie* 1995;96:939-43.
15. Sutor AH, Uhl M. Diagnosis of thromboembolic disease during infancy and childhood. *Semin Thromb Haemost* 1997;23:237–46.
16. David M, Andrew M. Venous thromboembolic complications in children. *J Pediatr*. 1993;123:337–46.
17. Bertoia A, Barrellier MT, Nguuyen-van V, Berger L, Le Hello C. Incidence and distribution of 1026 lower limb venous thrombi diagnosed by ultrasonography in 3263 patients with cancer. *J Mal Vasc* 2013;38:243-251.
18. Hirsh J, Lee AY. How we diagnose and treat deep vein thrombosis. *Blood* 2002;99:3102–10.
19. Monagle P, Adams M, Mahoney M, Ali K, Barnard D, Bernstein M, et al. Outcome of pediatric thromboembolic disease: a report from the Canadian Childhood

- Thrombophilia Registry. *Pediatr Res* 2000; 47:763–6.
20. Nuss R, Hays T, Manco-Johnson M. Childhood thrombosis. *Pediatrics* 1995; 96:291–4.
21. Rosendal FR. Thrombosis in the young: epidemiology and risk factors. A focus on venous thrombosis. *Blood* 2002;99: 3102–10.

---

© 2022 Mulendélé et al.; This is an Open Access article distributed under the terms of the Creative Commons Attribution License (<http://creativecommons.org/licenses/by/4.0>), which permits unrestricted use, distribution, and reproduction in any medium, provided the original work is properly cited.

*Peer-review history:*

*The peer review history for this paper can be accessed here:*  
<https://www.sdiarticle5.com/review-history/90578>