



Evaluation of Traumatic Injuries of Median and Ulnar Nerves at the Wrist after Surgical Repair: Ultrasound and Electrophysiological Correlation

**Omnia F. Saif^{1*}, Radwa M. El-khouly¹, Hamdy A. Khallaf¹, Fahima S. Rihan¹,
Salwa E. Abd El Ghany¹**

¹Physical Medicine, Rheumatology, and Rehabilitation Department, Faculty of Medicine, Tanta University, Tanta, Egypt.

Authors' contributions

This work was carried out in collaboration among all authors. All authors read and approved the final manuscript.

Article Information

DOI: 10.9734/JAMMR/2021/v33i1631008

Editor(s):

(1) Dr. Mohamed Essa, Sultan Qaboos University, Oman.

Reviewers:

(1) A. G. Joshi, Krishna Institute of Medical Sciences (Deemed to be University). (KIMSDU), India.

(2) Cheng-Jen Chang, Taipei Medical University, Taiwan.

Complete Peer review History: <https://www.sdiarticle4.com/review-history/70233>

Original Research Article

Received 30 April 2021

Accepted 01 July 2021

Published 20 July 2021

ABSTRACT

Aims: To quantify the contribution of ultrasonography (US) as a complementary tool to electrodiagnostic evaluation of traumatic lesions of median and ulnar nerves after surgical repair"

Patients and Methods: The study included a total of 50 nerves from 40 patients with traumatic injury of wrist median and/ or ulnar nerves. Patients were evaluated at one and three months after primary nerve repair clinically, electrophysiological, and US examinations.

Results: No significant difference ($p = 0.125$) was found between classification of injury by electrodiagnosis and by US. Good agreement between clinical assessment of the motor power and the severity of injury based on electrodiagnosis was found. Moderate agreement between clinical assessment of motor power and continuity of the repaired nerve based on US was noted. Good agreement between the severity of the injury by electrodiagnosis and the continuity of the repaired nerve by the US ($p < 0.001^*$) was detected. The sensitivity of US in detecting nerve continuity was 87.9% one month after repair and 80% after three months.

Conclusion: As a supplement to electrodiagnostic testing, the US can offer a noninvasive and complementary tool for assessing post-operative repair of traumatic nerve lesions with respect to

*Corresponding author: E-mail: OmniaSaif2017@gmail.com;

their exact location, course, continuity, extent, and neuroma formation and can be of value in the visualization of the morphological abnormalities associated with nerve injuries, including swelling and perilesional scar tissue formation.

Keywords: Traumatic peripheral nerve injury; electrodiagnosis; ultrasound.

1. INTRODUCTION

Traumatic peripheral nerve injuries (PNIs) are common in clinical practice due to motor vehicle accidents and less commonly from penetrating trauma, falls, and industrial accidents resulting in considerable disability across the world [1]. It is estimated that roughly 2 to 3% have peripheral nerve injuries. In the upper limb, the nerve most reported injured is the radial nerve, followed by ulnar and median nerves [1].

Neurophysiological testing, which includes nerve conduction studies and needle electromyography, can identify re-innervation potential during recovery. A needle EMG, an early sign of reinnervation is the appearance of "nascent" motor units representing activation of a few muscle fibers by newly sprouting axons; the morphology of motor units change as the sprouting axons mature and the motor units get reorganized. Serial electrophysiological testing is of value as an adjunct to the clinical assessment to evaluate the regeneration process and help to decide on the correct treatment strategy. In specific clinical situations such as the need for and timing of secondary surgical interventions, electrophysiological testing may add valuable information and help one decide if surgical re-exploration is required [2].

With the advances in musculoskeletal ultrasound technology, it has already been established as an effective tool in the diagnosis and evaluation of peripheral nerve disorders [3]. Ultrasound (US) addresses two key limitations of electrodiagnostic testing, the inability to provide anatomic detail and discomfort. Ultrasound is painless, being among the least invasive methods of medical diagnostic testing, and provides a view of the anatomy of nerve as well as of surrounding structures [4]. In traumatic peripheral nerve injuries, US can reveal the discontinuity of the nerve, perilesional scar tissue, and presence of a neuroma [5].

Our study aimed to quantify the contribution of ultrasonography (US) as a complementary tool to electrodiagnostic for evaluation of Surgical repair of traumatic median and ulnar nerve lesions.

3. PATIENTS AND METHODS

This study was carried out on 40 patients with laceration injury of the median and/or ulnar nerve at the wrist after nerve repair referred from Plastic Surgery Department to be evaluated at the Physical Medicine, Rheumatology and Rehabilitation Department, Tanta University Hospitals. All the patients underwent primary surgical nerve repair. Patients with peripheral neuropathy, radiculopathy affecting the upper limbs, or plexopathy of brachial plexus were excluded from the study. Written informed consent was obtained from all the participants. The research was conducted in line with the ethical principles of the Declaration of Helsinki. The study was accepted by Tanta University's Faculty of Medicine's Local Research Ethics Committee.

Patients were evaluated at one and three months after primary nerve repair clinically and by electrophysiological & ultrasound examination.

All patients were subjected to thorough history taking and clinical examination to detect motor and sensory deficits. Motor function was assessed according to the 0-5 grades of the "Nerve Injuries Committee" of the British Medical Research Council [6].

The electrophysiological studies of the repaired median and/ or ulnar nerves were done using the Nihon Neuropack 2, 2 channels apparatus. Routine motor nerve conduction studies (NCS):

A. Median motor: stimulate at wrist and elbow and record from APB (Abductor pollicis brevis). Median sensory: stimulate at wrist and record over digit 2.

B. Ulnar motor: stimulate at wrist, below elbow, above elbow and record from ADM (Abductor digiti minimi). Ulnar sensory: stimulate at wrist and record over digit 5 [7].

Needle electromyography (EMG) was performed for the muscles supplied by the affected nerve using a concentric needle [7]. Based on the interpretation of nerve conduction studies &

electromyography the type and severity of nerve injury were classified.

All patients were examined at the ultrasonography unit of Physical medicine, Rehabilitation & Rheumatology Department in Tanta University Educational Hospital using SAMSUNG MEDISON (UGEO H60).

US Technique: The patients were seated facing the examiner while their forearms in extended supination position, their wrists in neutral position and their fingers placed on the table in semi extended position. The linear transducer (frequency 9- 13 MHz) was placed directly on the patient's skin with gel. The injured nerve was first identified on a transverse sonogram near a known anatomical landmark proximal to the damaged region. Then the transducer was gradually moved toward the damaged region and the nature of the lesion in the nerve was determined. Then, the fascicles, perineurium, epineurium of the affected nerve were examined in transverse and longitudinal planes [8]. the following criteria were determined: The maximum cross-sectional area (CSA) of the nerve: at the level of the site of repair, it was measured using a direct tracing method using the inner margin of the hyperechoic sheath as the margin of the nerve [8].

The echogenicity of the nerve was evaluated. Fascicular continuity was assessed and the hypoechoic gap between the two ends of the nerve was measured. Also, we searched for the presence or absence of perilesional scar tissue or neuroma formation [8].

2.1 Statistical Analysis

Data were fed to the computer and analyzed using IBM SPSS software package version 20.0. (Armonk, NY: IBM Corp) Qualitative data were described using number and percent. The Kolmogorov-Smirnov test was used to verify the normality of distribution Quantitative data were described using range (minimum and maximum), mean, standard deviation, median, and interquartile range (IQR). The significance of the obtained results was judged at the 5% level. The used tests were: Chi-square test: for categorical variables, to compare between different groups. Fisher's Exact: correction for chi-square when more than 20% of the cells have expected count less than 5. McNemar and Marginal Homogeneity test: used to analyze the significance between the different stages. Wilcoxon signed ranks test: for abnormally

distributed quantitative variables, to compare between two periods. Kappa (κ): was used for the concordance.

3. RESULTS

This study included 30 male patients (75%) and 10 female patients (25%). The patient's age ranged from 13-53 years, with a mean age of 27.73 ± 8.42 years. The median nerve was injured in 20 cases, the ulnar nerve was injured in 10 cases, while the other 10 cases had both median and ulnar nerve injuries.

The nerve injury in our study was primarily caused by shards of glass in 25 cases (62.5%). However, in 11 cases, 27.5% were injured by knives, and in 3 cases, 7.5% were injured with sharp machines, and yet, in only one case (2.5%) a sword caused the injury.

The clinical neurological examination includes sensory, and the power of the muscles supplied by the affected nerves (Figs. 1 a and b, 2).

In our study, the injured peripheral nerve was examined via US one month and three months after repair, with the finding of the following criteria: cross-sectional area (CSA), echogenicity, fascicular continuity, and the overall integrity of the nerve and perilesional scar tissue formation shown in (Table 1).

Complete nerve lesion was found in 33 nerves (66%) whereas 17 nerves (34%) showed partial nerve lesion at 1 month after repair. At three months after repair, a Complete nerve lesion was found in 30 nerves (60%) and a partial nerve lesion in 20 nerves (40%). The continuity of the nerve by the US was demonstrated with no significant difference between electrodiagnosis and US, given the studied nerves at one and three months, after repair.

When correlated, there was a significant difference in the diagnosis of nerve injury by electrophysiology and US at one and three months, after repair (Table 2).

There was good agreement between motor power and severity of the injury by electrodiagnosis, along with moderate agreement between motor power and continuity of the injured nerve with US (Table 3). Also, there was agreement between the severity of the injury by electrodiagnosis and continuity of the injured nerve by US (Fig. 2).

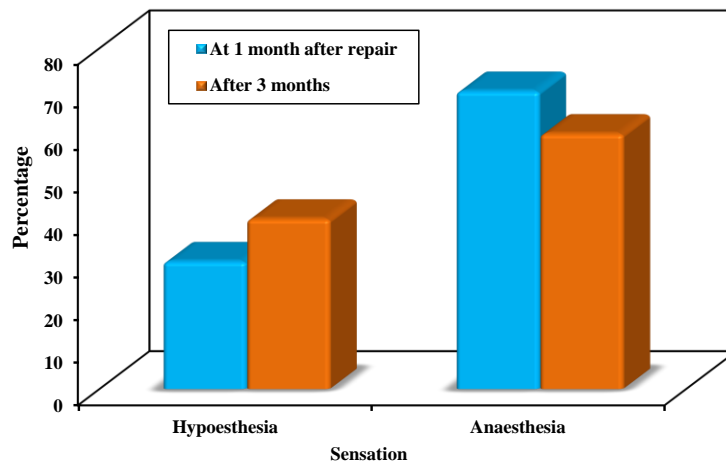
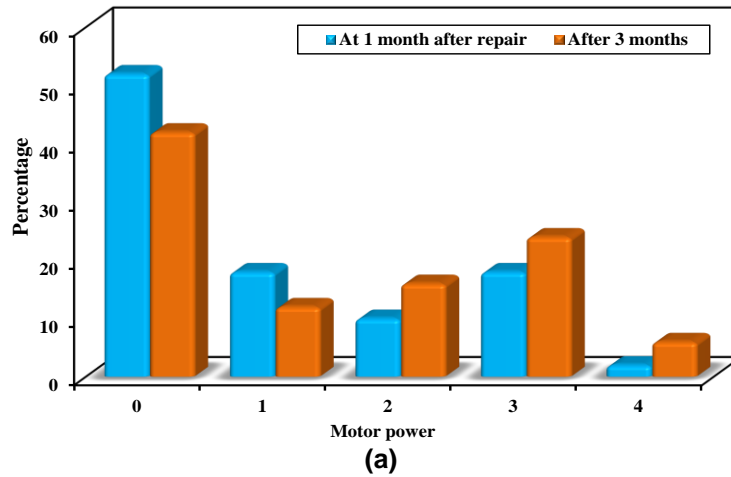


Fig. 1. (a): Comparison between the motor power of the repaired nerves at 1 month and 3 months after repair (n = 50) (b): Comparison between the Sensation of the repaired nerves at 1 month and 3 months

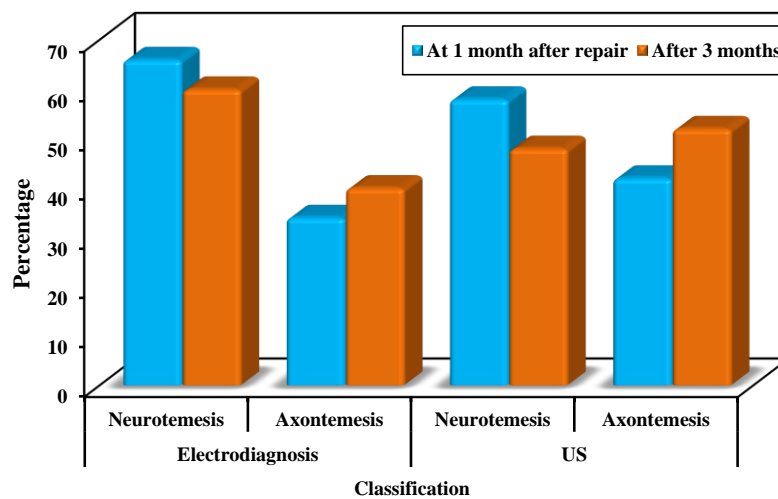


Fig. 2. Comparison between the classification of the injury by electrodiagnosis & US of all the studied nerves at 1 month and 3 months after repair (n=50)

Table 1. Comparison between the US findings at 1 month and 3 months after repair in all the studied nerves (n = 50)

US findings	At 1 month after repair		After 3 months		Test of sig.	P
Maximum CSA (mm²)						
Min. – Max.	14.0 – 51.0		7.0 – 48.0		Z=0.976	0.329
Mean ± SD.	26.98 ± 11.74		25.05 ± 10.79			
Median (IQR)	24.0(17.0 – 32.0)		23.0(17.0 – 34.50)			
Longitudinal gap (cm)						
Min. – Max.	0.28 – 1.29		0.23 – 1.20		Z=4.412*	<0.001*
Mean ± SD.	0.71 ± 0.31		0.59 ± 0.28			
Median (IQR)	0.57 (0.47 – 1.01)		0.50 (0.40 – 0.80)			
Continuity	No.	%	No.	%		
Discontinuous	29	58	24	48.0	$\chi^2=0.802$	McN=0.125
Continuous	21	42.0	26	52.0		
Echogenicity						
Hypoechoic	50	100.0	35	70.0	$\chi^2=12.75$	McN=0.001*
Heterogeneous	0	0.0	15	30.0		
Scar tissue						
Absent	35	70.0	38	76.0	$\chi^2=0.065$	McN=1.000
Present	15	30.0	12	24.0		

χ^2 : Chi-square test, McN: McNemar test, Z: Wilcoxon signed ranks test, p: p-value for comparing between 1 month and 3 months after repair, *: Statistically significant at $p \leq 0.05$

Table 2. Relation between nerve injury by electrophysiology and by ultrasound at 1 & 3 months after repair in all the studied nerves (n=50)

	Continuity by US at 1 month after repair				χ^2	P
	Discontinuous (n=29)		Continuous (n=21)			
	No.	%	No.	%		
Severity						
Partial	0	0.0	17	81.0	23.193*	<0.001*
Complete	29	100.0	4	19.0		
	Continuity by US at 3 months after repair				χ^2	P
	Discontinuous (n=24)		Continuous (n=26)			
	No.	%	No.	%		
Severity						
Partial	0	0.0	20	77.0	21.714*	<0.001*
Complete	24	100.0	6	23.0		

χ^2 : Chi square test, FE: Fisher Exact, p: p value for association between different categories, *: Statistically significant at $p \leq 0.05$

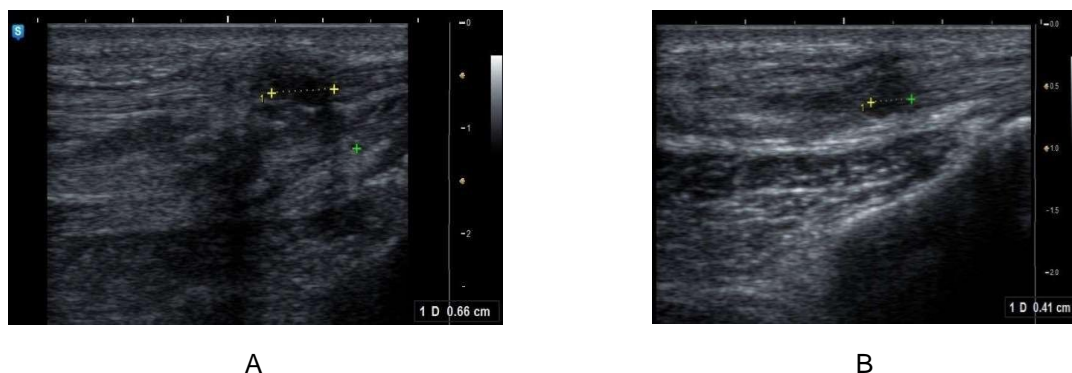


Fig. 3. Longitudinal view of Rt. median nerve at the site of trauma at the wrist A “at one month after repair” and B “at three months after repair”

Table 3. Kappa test for the concordance between the severity of the injury by electrodiagnosis & the continuity of the injured nerve by US at 1 & 3 months after repair in all studied nerves (n=50)

	Severity of the injury by the electrodiagnosis at 1 month after repair				χ^2	P
	Complete (n = 33)		Partial (n = 17)			
	No.	%	No.	%		
Continuity by US						
Discontinuous	29	87.9	0	0.0	23.193*	<0.001*
Continuous	4	12.1	17	100.0		
Kappa (p)	0.734* (<0.001*)					
Level of agreement	Good agreement					
	Severity of the injury by the electrodiagnosis at 3 months after repair				χ^2	P
	Complete (n = 30)		Partial (n = 20)			
	No.	%	No.	%		
Continuity by US						
Discontinuous	24	80.0	0	0.0	21.714*	<0.001*
Continuous	6	20.0	20	100.0		
Kappa (p)	0.704* (<0.001*)					
Level of agreement	Good agreement					

The sensitivity of US in detecting nerve continuity was 87.9% one month after repair, and 80% three months after repair (Fig. 3).

4. DISCUSSION

Hand injuries are common, accounting for 5 to 10% of emergency department injuries and 4.7% of all trauma patients. Traumatic peripheral nerve injuries (PNI) are a major cause of severe and permanent loss of hand function [9].

Electrodiagnostic studies (EDX) that include NCSs and EMGs are the gold standard for localizing and assessing the severity of a PNI: it contributes significant information about the diagnosis, along with surgical planning and postoperative follow-up of traumatic PNIs. However, these methods do not provide information about the morphology or anatomy of nerves [10].

US has a role in the assessment of traumatic neuropathies, as it assesses continuity and integrity of the nerve, characterizes the defect, and identifies secondary nerve compression [11]. Thus, location, extent, and type of damage can be determined. This displays a complete and partial nerve transection, the distance and condition of the stumps (formation of a neuroma), or compression of the nerve: created by scars, callus formations. US can change or significantly modify a diagnosis and provide

information in cases of traumatic nerve injury [11].

In this study, the most common injury was to the median nerve (60%). This stance agrees with Jaquet et al. [12] who reported a higher incidence of injuries of the median nerve vs. the ulnar nerve. However, this was in disagreement with Kouyoumdjian J [13], whose retrospective survey on 456 cases showed that the ulnar nerve was most often injured in the upper limbs, singly or in combination, clarified by its superficial course in the upper limb; this can be discussed in our study, which includes cases with nerve injuries at the wrist but not to the whole upper limb.

As stated, nerve injury in our study was predominantly imposed by shards of glass in 25 cases (62.5%). Coinciding with Noaman [14] whose study showed that the most common cause of wrist injuries was broken glass, followed by knife stabs.

Upon EMG examination at one month after repair, denervation activity, “fibrillation potentials and positive sharp waves” was detected in 100% of cases from denervated muscles that were still present, but gradually decreased after three months. This is explained by Robinson L [15] and Krarup C, et al., [16] who stated that motor unit potential (MUP)s could first be quantified at 3 to 19 months after repair, and when compared over time after nerve repair; that is, the number

of recorded MUPs in the muscles increased over several months. In terms of electrodiagnosis of postoperative repair of nerve injury, Robinson L [15] stated that abnormal neurogenic MUPs can be explained by collateral sprouting following incomplete axonal loss. The surviving motor axons create collateral sprouts from nerve terminals near the muscle fibers, which lost innervation to reinnervate muscle fibers in days to weeks. While absent MUPs are due to nerve injury, this refers to a non-excitable distal aspect of the injury, with an electrophysiologically complete lesion.

In the first US examination, one month after a repair, and increased cross-sectional area (CSA) was shown, denoting nerve swelling, hypoechogenicity in 100% of cases, with 29 nerves still having a hypoechoic gap between the two ends of the nerve, while 21 nerves showed fascicular continuity and perilesional scarring in 30% of cases. After three months, the US examination showed gradual improvement of all parameters with a statistically significant difference in the longitudinal gap and echogenicity. Improvement was identified by decreased CSA of the injured nerves and decreased measure of the hypoechoic gap, improved fascicular continuity in five nerves, and improved echogenicity in 15 heterogeneous nerves. This agreed with Peer S, et al., [17] who evaluated that 19 patients underwent primary direct nerve repair after peripheral nerve injuries and concluded that US may serve as a valuable diagnostic adjunct for follow-up, especially with patients having persistent functional impairment after primary nerve reconstruction.

The ultrasonographic findings of the nerve injury studied by Domkundwar S, et al., [18] showed increased nerve CSA and hypoechogenicity, as explained by increased intraneural edema leading to reduced echogenicity, loss of fascicular pattern, and nerve thickening.

In our study, nerve injuries were categorized based on Seddon's classification into (axonotmesis and neurotmesis) by electrodiagnosis and US. Axonotmesis for nerve injuries with reduced compound muscle action potential (CMAP) and sensory nerve action potential (SNAP) amplitudes and fibrillations by electrodiagnosis and US evidence of hypoechogenicity, loss of fascicular pattern, and normal or partial continuity due to neuroma. Neurotmesis for nerve injuries with reduced or absent CMAP and SNAP, fibrillation and motor

unit loss seen by electrodiagnosis and damaged nerve continuity or terminal neuroma as seen by US [19].

There was agreement between electrodiagnosis and US on classification of the injury at one and three months after repair, confirming that US is a sensitive tool in classifying PNIs. This agreed with Zhu J, et al., (2011) [20] who found that in the 117 cases with PNIs discussed in the literature, the accuracy of classification of nerve injury with US was 93.2%.

In our study, one month after repair, EDX revealed that 33 cases had complete nerve injury, four of which showed fascicular continuity by US. After three months, EDX revealed 30 cases with complete nerve injury, with six appearing to be continuous with the US. We found a statistically significant difference between diagnosis of the severity of nerve injury by EDX and continuity of the nerve by US at one and three months after repair. This agreed with the study done by Elfayoumy N, et al., (2020) [21] in which they studied 12 nerves diagnosed as complete nerve injuries with the use of EDX, but using US, only three nerves showed fascicular continuity. Lauretti L, et al., [22] found that complete anatomical nerve interruption is easily recognized by the US, while internal nerve damage with the epineurium in continuity is more difficult to interpret.

We found agreement between clinical assessment of motor power and the severity of the injury by electrodiagnosis, at one and three months after repair. This agrees with Şahin F, et al., [23] who studied the link between electrodiagnostic findings and functional status, muscle strength, and sensibility in patients with traumatic nerve injury to the wrists; we concluded that recovery of muscle grade and sensibility is correlated with CMAP and SNAP amplitudes, respectively.

However, other studies evaluating the correlation of electrophysiological findings with functional assessments have reported inconsistent results. Valero-Cabré A, et al., [24] reported no correlation between electrophysiological findings and functional viability, attributing this to the misdirection of axonal growth and the reinnervation of muscles by inappropriate motor neurons.

A moderate level of agreement was found between motor power and findings of the US in

our study, at one and three months after repair. This agreed with Lu M, et al., [25] in his study of nerve injuries that determine concordance between clinical and US outcomes.

A good level of agreement was deduced in our study between severity of injury by electrodiagnosis and continuity of the injured nerve by US, at one and three months after repair. The sensitivity of US in detecting nerve continuity was 87.9% in the first presentation one month after repair, and 80% three months after repair at follow-up. This agreed with the study done by Elfayoumy N, et al., [22] in which US sensitivity in detecting nerve continuity was found to be 75%.

This was also in agreement with Gagliardo A, et al., [26] who reported that neurophysiological and clinical parameters are good predictors of postsurgical recovery, but high-resolution US demonstrated its usefulness when correlated with clinical neurophysiology.

To our knowledge, there is not a similar study for the correlation between NCS and US in the evaluation of postoperative repair of nerve injuries.

5. LIMITATIONS OF THE STUDY

In this study, patients were evaluated at one and three months after the primary. nerve repair and this was a short period for the follow-up to gain markedly different outcomes. We recommend the follow-up in cases with nerve repair to be at least 6 months after the repair.

6. CONCLUSION

As a supplement to electrodiagnostic testing, the US can offer a noninvasive and complementary tool for assessing surgical repair of traumatic nerve lesions concerning their exact location, course, continuity, extent, and neuroma formation and can be of value in the visualization of the morphological abnormalities associated with nerve injuries, including swelling and perilesional scar tissue formation. The addition of US to electrophysiological study is very valuable for follow-up of repaired peripheral nerve after traumatic injuries.

CONSENT AND ETHICAL APPROVAL

Written informed consent was obtained from all the participants. The research was conducted in

line with the ethical principles of the Declaration of Helsinki. The study was accepted by Tanta University's Faculty of Medicine's Local Research Ethics Committee.

COMPETING INTERESTS

Authors have declared that no competing interests exist.

REFERENCES

1. Robinson L. Traumatic injuries to peripheral nerves. John Wiley & Sons, Inc. 2000;23:863-873.
2. Van de Kar H, Jaquet J, Meulstee J, Molenaar C, et al. Clinical value of electrodiagnostic testing following repair of peripheral nerve lesions: A prospective study. *J Hand Surg Br.* 2002;27(4):345-349.
3. Cokluk C and Aydin K. Ultrasound examination in the surgical treatment for upper extremity peripheral nerve injuries. Part I. *Turk Neurosurg.* 2007;17:277-282.
4. Suk J, Walker F, Cartwright M. Ultrasound of peripheral nerves. *Curr Neurol Neurosci Rep.* 2013;13(2): 328.
5. Chen K, Lee K, Hsu H, Huang W, et al. The role of high-resolution ultrasound in the diagnosis of a traumatic neuroma in an injured median nerve. *Am J Phys Med Rehabil.* 2009;88:771-774.
6. Desphande A. Estimation of hand muscle power. *IOSR Journal of Electrical and Electronics Engineering.* 2016;11(3):40-42.
7. Pease W, Lew H, Johnson E. Johnson's practical electromyography. 4th ed. Lippincott Williams &Wilkins. 2007;Chapter 9:233.
8. Cartwright M, Chloros G, Walker F, Wiesler E, et al. Diagnostic ultrasound for nerve transection. *Muscle Nerve.* 2007;35:796-799.
9. Nouraei M, Hosseini A, Salek S, Nouraei F, et al. Median and ulnar nerve injuries; what causes different repair outcomes?. *Adv Biomed Res.* 2015;4:215.
10. Miranda G and Torres R. Epidemiology of traumatic peripheral nerve injuries evaluated with electrodiagnostic studies in a tertiary care hospital clinic. *Puerto Rico Health Sci J.* 2016;35(2):76-80.
11. Padua L, Martinoli C. From square to cube: ultrasound as a natural complement of neurophysiology. *Clin Neurophysiol.* 2008;119(6):1217-1218.

12. Jaquet J, Luijsterburg A, Kalmijn S, Kuypers P, et al. median, ulnar, and combined median-ulnar nerve injuries: Functional outcome and return to productivity. *J Trauma*. 2001;51(4):687-692.
13. Kouyoumdjian J. peripheral nerve injuries a retrospective survey of 456 cases. *Muscle Nerve*. 2006;34:785–788.
14. Noaman H. Management and functional outcomes of combined injuries of flexor tendons, nerves, and vessels at the wrist. *Microsurgery*. 2007;27(6):536-543.
15. Robinson L. How electrodiagnosis predicts clinical outcome of focal peripheral nerve lesions. *Muscle Nerve*. 2015;52(3): 321–33.
16. Krarup C, Boeckstyns M, Ibsen A, Moldovan M, et al. Remodeling of motor units after nerve regeneration studied by quantitative electromyography. *Clin Neurophysiol*. 2015;127(2):1675-1682.
17. Peer S, Harpf C, Willeit J, Piza-Katzer H, et al. Sonographic evaluation of primary peripheral nerve repair. *J Ultrasound Med*. 2003;22 (12):1317-1322.
18. Domkundwar S, Autkar G, Khadilkar S, Virarkar M. Ultrasound and EMG–NCV study (electromyography and nerve conduction velocity) correlation in diagnosis of nerve pathologies. *J Ultrasound*. 2017;20(2):111-122.
19. Deniel A, Causeret A, Moser T, Rolland Y, et al. Entrapment and traumatic neuropathies of the elbow and hand: An imaging approach. *Diagn Interv Imaging*. 2015;96(12):1261-1278.
20. Zhu J, Liu F, Li D, Shao J, et al. Preliminary study of the types of traumatic peripheral nerve injuries by ultrasound. *Eur Radiol*. 2011;21(5):1097–1101.
21. Elfayoumy N, Elgendy H, Saad M, and Labib A. Role of nerve ultrasound versus electrophysiological studies in the evaluation of nerve injuries. *The Egyptian Journal of Neurology, Psychiatry, and Neurosurgery*. 2020;56:33.
22. Lauretti L, D'Alessandris Q, Granata G, Padua L, et al. Ultrasound evaluation in traumatic peripheral nerve lesions: From diagnosis to surgical planning and follow-up. *Acta Neurochirurgica*. 2015;157(11):1947–1951.
23. Şahin F, Atalay N, Akkaya N, Ercidoğan Ö, et al. The correlation of neurophysiological findings with clinical and functional status in patients following traumatic nerve injury. *J Hand Surg Eur*. 2014;39(2):199-206.
24. Valero-Cabré A, Navarro X. Functional impact of axonal misdirection after peripheral nerve injuries followed by graft or tube repair. *J Neurotrauma*. 2002;19(11):1475-1485.
25. Lu M, Wang Y, Yue L, Chiu J, et al. Follow-up evaluation with ultrasonography of peripheral nerve injuries after an earthquake. *Neural Regen Res*. 2014;9(6):582–588.
26. Gagliardo A, Toia F, Maggi F, Mariolo A, et al. Clinical neurophysiology and imaging of nerve injuries: preoperative diagnostic workup and postoperative monitoring. *Plast Aesthet Res*. 2015;2:149-155

© 2021 Saif et al.; This is an Open Access article distributed under the terms of the Creative Commons Attribution License (<http://creativecommons.org/licenses/by/4.0>), which permits unrestricted use, distribution, and reproduction in any medium, provided the original work is properly cited.

Peer-review history:

*The peer review history for this paper can be accessed here:
<https://www.sdiarticle4.com/review-history/70233>*