



Fentanyl Intoxication in an Eight Years Old Child after Application of 75 µg/h Transdermal Patch: A Case Report

A. Chlouchi ^{a*}, R. Cherkaoui ^a, H. Lahyani ^a, A. Bentalha ^a, A. Elkoraichi ^a
and S. Echcherif El-Kettani ^a

^a Pediatric Intensive Care Department, Faculty of Medicine and Pharmacy of Rabat, Rabat Children's Hospital, Avicenne Teaching Hospital of Rabat, Mohamed V University of Rabat, Morocco.

Authors' contributions

This work was carried out in collaboration among all authors. All authors read and approved the final manuscript.

Article Information

DOI: 10.9734/IJMPCR/2022/v15i4321

Open Peer Review History:

This journal follows the Advanced Open Peer Review policy. Identity of the Reviewers, Editor(s) and additional Reviewers, peer review comments, different versions of the manuscript, comments of the editors, etc are available here: <https://www.sdiarticle5.com/review-history/95376>

Received 18 October 2022
Accepted 27 December 2022
Published 29 December 2022

Case Study

ABSTRACT

Opioid intoxication in pediatrics is rare in Morocco. In the children's hospital of Rabat, it is the third case that has been recorded in recent years. It is about a boy of 8 years old who after a benign trauma at the level of the back, his father attached to him a patch of fentanyl dosed at 75 µg/h given by a friend returning from abroad. After 8 hours, the father found his child unconscious with abnormal breathing, motivating him to bring him back to the emergency room of the hospital. He presented a convulsive seizure before being urgently intubated and transferred to intensive care unit. He received a triple dose a day in addition to a continuous infusion of 0,4 milligram of Naloxone. The patient woke up and was extubated after 24 hours, but he kept a divergent strabismus of the right eye for which he was sent to the ophthalmology department for further management. We highlight through this case report the severity of pediatric opioid intoxication and underscores the importance of primary prevention in combating this scourge.

Keywords: Intoxication; fentanyl; child; management; prevention.

1. INTRODUCTION

Fentanyl is a third tier opioid analgesic, marketed as an injectable or transdermal patch, and prescribed for the management of acute and chronic pain.

The increasing prescription of these drugs for adults is strongly associated with increased exposure and intoxication in children.

We describe here a case of acute intoxication at home by a fentanyl patch in an 8 years old boy in a context of misuse.

2. CASE REPORT

Child E.A aged 08 years, brought by his father to the medical emergency of the children's hospital of Rabat on 12/09/2022 at 5 am for unconsciousness and abnormal breathing.

The child had no particular medical history. In his surgical history, we note a circumcision at the age of 2 years done under locoregional anesthesia.

The story goes back to the evening of 11/09/2022 around 9 pm when the child presented lumbar pain following a fall during a soccer game. The father stuck a fentanyl patch at 75 µg/h on his back in the painful area (Image 1) given by a friend coming back from abroad.

At 5 am, the father woke up for prayers and noticed that his child had abnormal breathing and did not wake up despite the stimuli. The father quickly removed the patch and brought the child back to the emergency room of the hospital.

The patch remained attached for 8 hours, which is an equivalent dose of 600 µg of fentanyl delivered.

In the emergency room, the patient has presented a generalized seizure that had ceased under 2 milligram of intravenous Midazolam.

Clinical examination in the emergency room found the patient unconscious with a Glasgow Coma Scale of 4/15 (EO=1, VR=, MR=2) pupils in serous myosis. The patient presented a stertorous breathing, was cyanotic, pulse saturation between 88 and 92% under oxygen at 10 l/min. Diffuse snoring murmurs on auscultation. He was hemodynamically stable with a BP of 110/66 mmhg with a HR of 101 bpm. His glycaemia was at 1.5 g/l, Temperature at 36.8°C and his Weight was 30 kg.

We decided to intubate the patient on site. After conditioning and monitoring, we took a peripheral venous line and fill with 200 cc of saline 0.9%, and a urinary catheter was inserted. Complementary induction with 150 mg of propofol and 20 mg of rocuronium, then orotracheal intubation with a size 5 tube fixed, marker at 15 cm to the dental arch.

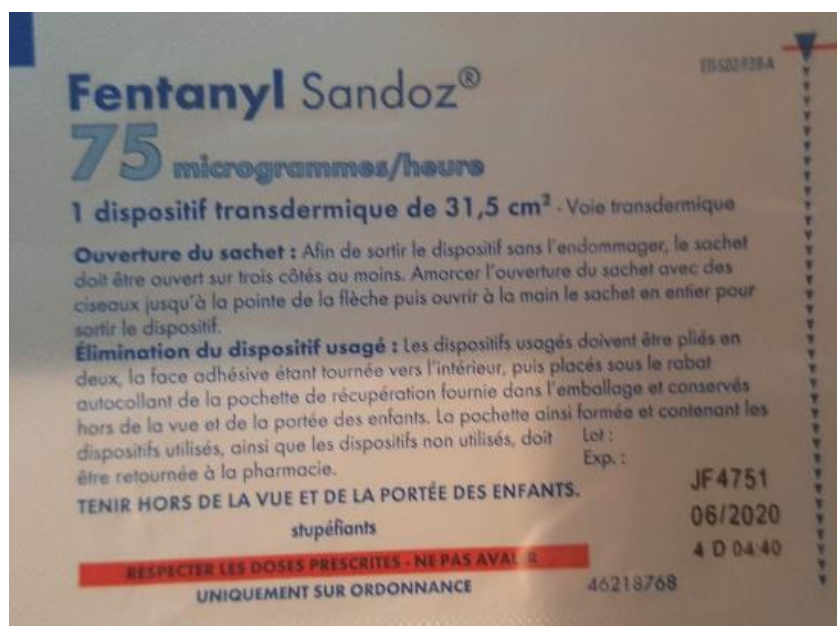


Fig. 1. Packaging of the fentanyl patch used

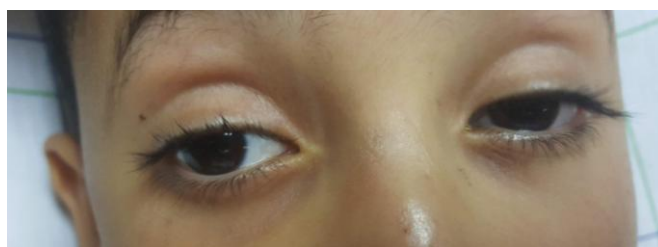

Fig. 2. Divergent strabismus of the right eye as a neurological sequel

Then we transferred the patient to the pediatric intensive care unit for further management.

In the intensive care unit, the patient underwent the following assessment: Blood cells count and ions was normal, the blood gases also. The cranial CT scan revealed no abnormalities.

We start the following treatment by 0.4-milligram bolus of naloxone three times a day, in addition to a continuous 0.4 milligram of naloxone infusion. We notified the toxicology center by e-mail.

The evolution was marked by the patient's awakening after 24 hours of mechanical ventilation allowing him to be extubated. The complete clinical examination after extubation showed a divergent strabismus of the right eye probably related to anoxia (Fig. 2). A brain MRI was performed, it showed any abnormalities.

The patient was discharged from the intensive care unit after 48 hours and referred to the ophthalmology department for further management.

3. DISCUSSION

Fentanyl is an opioid analgesic, derived from phenylpiperidine, which interacts primarily at μ -morphine receptors in the brain, spinal cord and smooth muscle.

It has a rapid analgesic effect and a short duration of action. Fentanyl has an analgesic effect approximately 100 times more potent than morphine. Its main therapeutic effects are analgesic and sedative.

The fentanyl patch is indicated in the long-term treatment of severe chronic pain in children from 2 years of age receiving opioid analgesics for the treatment of chronic pain of cancerous origin, intense or resistant to analgesics, in case of stable pain [1].

The application of fentanyl transdermal patches has resulted in significant morbidity and mortality since their development.

However, there are few studies concerning fentanyl intoxication in pediatrics.

In this patient, it is a case of intoxication by misuse of a fentanyl patch intended for adults and dosed at 75 μ g/hour. The young child received a total equivalent dose of 600 micrograms during 8 hours.

The most serious and feared adverse effect of opioids is respiratory depression. Deaths secondary to opioids occur because of decreased sensitivity to hypoxia and hypercapnia that cause respiratory depression. Fentanyl is known to cause chest rigidity due to muscle spasm [2].

Myosis, nausea and vomiting, pruritus, constipation, and urinary retention are also frequently reported symptoms of overdose [3].

In this patient, the clinical presentation was dominated by generalized tonicoclonic seizure most likely of hypoxic origin in addition to bradypnea and tight myosis.

In this case, the management of the patient consisted in the support of the respiratory function by mechanical ventilation associated with naloxone administered in bolus of 0.4 mg each eight hours associated with a continuous infusion of 0.4 mg in 24h.

Naloxone is a pure and specific antagonist of morphinomimetics. When injected into patients who have received morphinomimetics, naloxone antagonizes their effects (respiratory depression, myosis, analgesia). Its action depends on the dose, the potency of the morphinomimetic to be antagonized and the interval between injections of the two products [4,5].

It is administered in case of toxic coma at the dosage of 0.4 mg three times a day from the age of 3 years with a maximum dosage of 10 mg/24h [6].

Despite the Naloxone, the patient's awakening was obtained only after 24 hours of respiratory assistance testifying to the importance of the dose received and the duration of exposure, the clinical examination after extubation found a divergent strabismus of the right eye as a sequel. [7].

In this case, the neurological lesion may be due to direct neurotoxicity or secondary to hypoxia induced by respiratory depression.

In this referral hospital, this is the third case of accidental morphinomimetic intoxication that has been recorded and the national data concerning these intoxications in pediatrics are insufficient.

Internationally, several studies have shown that morphinomimetic intoxication has become epidemic with devastating consequences for children and their families due to the increase in the prevalence of opioid use and abuse [7,8].

Given the easy access to these drugs, accidental ingestion and misuse in children is becoming increasingly common [9].

Prevention remains the most effective means of combating these tragedies and that includes educating patients about the potential risks and proper use [10].

Pharmaceutical companies must step up their efforts to make fentanyl patch safety a top priority. Label warnings should be improved, and secure disposal containers for patches should be designed and made widespread.

Prescribers and pharmacists also need ongoing education regarding the proper use, storage, and disposal of opioid-containing products.

4. CONCLUSION

This case report highlights the severity of pediatric opioid intoxication and underscores the importance of primary prevention in combating this scourge.

Patient and caregiver education is the cornerstone of this prevention strategy.

Further studies must be undertaken in Morocco to evaluate the incidence and improve the management of these intoxications.

CONSENT

The patient's father as legal representant has given his approval for the publication of this clinical case.

ETHICAL APPROVAL

As per international standard or university standard written ethical approval has been collected and preserved by the author(s).

COMPETING INTERESTS

Authors have declared that they have no known competing financial interests or non-financial interests or personal relationships that could have appeared to influence the work reported in this paper.

REFERENCES

1. Geneviève Laflamme, Annie Lavoie Annie Lavoie. Opiates in children. *CHU-Sainte-Justine 3175 Côte Sainte-Catherine Montreal (Quebec) H3T 1C5*. Available:<http://collections.banq.qc.ca/ark:/52327/bs2318569>
2. Lindsey N Haut, Rupa Radhakrishnan, Riad Lutfi, Louise W Kao, Laurie L. Acute cytotoxic cerebellar edema subsequent to fentanyl patch intoxication in an infant. *Ackerman Hindawi Case Reports in Critical Care*. 2021;Article ID 9449565:5. Available:<https://doi.org/10.1155/2021/9449565>
3. Edouard Le Carpentier, Guillaume Deslandes, Laurent Boidin, Caroline Paget, Renaud Clément, Catherine Monteil-Ganière pharmacology-toxicology laboratory, Nantes University Hospital, Nantes, France Forensic Medicine, Nantes University Hospital, Nantes, France. Fatal poisonings by fentanyl misuse and opioid replacement therapy: description of 2 cases *EM Consult Volume 7230, Issue 1003, 09/2021, Pages S1-S64, ISSN 2352-0078*. Available:<http://dx.doi.org/10.1016/j.toxac.2021.06.051>
4. Hoizey G, Rey-Salmon C, Meyer P, Chèze M, Billault F, Médrano E, Deveaux M. Fatal

- poisoning of an infant by fentanyl: Homicide or accident? Toxlab laboratory, Paris, France, Medico-judicial unit of the Hôtel Dieu, Paris, France, Department of anaesthesia-resuscitation, CHU Necker, Paris, France. EM Consult. 2018;5971(1002):S1-S84. ISSN 2352-0078.
Available:<http://dx.doi.org/10.1016/j.toxac.2018.04.013>
5. Jörg Teske, Jens-Peter Weller, Klaus Larsch, Hans Dieter Tröger, Matthias Karst. Fatal outcome in a child after ingestion of a transdermal fentanyl patch. International Journal of Legal Medicine. 2007;121:147–151.
 6. Foy L, Seeyave DM, Bradin SA. Toxic leukoencephalopathy due to transdermal fentanyl overdose. Department of Pediatrics and Communicable Diseases, University of Michigan, Ann Arbor, MI, USA. *Pediatr Emerg Care*. 2011 Sep;27(9):854-6.
DOI: 10.1097/PEC.0b013e31822c281f.
PMID: 21926884.
 7. Matthew Grissinger Fentanyl Fatalities Patch. Fentanyl patch fatalities: We all have a role in prevention. We all Have a Role in Prevention! P T. 2016;41(7):405-6.
PMID: 27408513; PMC ID: PMC4927011.
 8. Stacy L Reynolds, Kathleen K Bryant, Jonathan R Studnek, Melanie Hogg, Connell Dunn. Randomized controlled feasibility trial of intranasal ketamine compared to intranasal fentanyl for analgesia in children with suspected extremity fractures. *Academic Emergency Medicine*. 2017;24(12).
Available:www.aemj.org
 9. El Kihel H, Arfaoui M, Chaker A, Bentalha A, Elkoraichi A, Echcherif El Kettani S. Accidental opioid intoxication in children treated with low doses of naloxone: A case of fentanyl patch exposure and a case of morphine tablet ingestion. Intensive care department, Children's Hospital of Rabat, Morocco *Scholars Journal of Medical Case Reports* ISSN 2347-9507 (Print) | ISSN 2347-6559. 2021;985-989.
 10. Rebecca T DeRienz, Daniel D Baker, Nancy E Kelly, Amber M Mullins, Rachel Y Barnett, Jennifer M Hobbs, John A Daniels, Kent E Harshbarger, Anahi M. Child fatalities due to heroin/ fentanyl exposure: What the case history missed. Ortiz Franklin County Coroner's Office, 520 King Avenue, Columbus, OH 43201, USA *Journal of Analytical Toxicology*. 2018;42: 581–585.
DOI:10.1093/jat/bky052

© 2022 Chlouchi et al.; This is an Open Access article distributed under the terms of the Creative Commons Attribution License (<http://creativecommons.org/licenses/by/4.0>), which permits unrestricted use, distribution, and reproduction in any medium, provided the original work is properly cited.

Peer-review history:

The peer review history for this paper can be accessed here:
<https://www.sdiarticle5.com/review-history/95376>