



Cardiac Protection Activity of Ethanol Extract of White Curcumin (*Curcuma Zedoaria*), Against Cyclophosphamid Induced Cardiovascular Complications in Male Rat

Addin Amrullah^{1*}, Florenly¹ and Edy Fachrial¹

¹*Faculty of medicine, Universitas Prima Indonesia, Medan, Indonesia.*

Authors' contributions

This work was carried out in collaboration among all authors. All authors read and approved the final manuscript.

Article Information

DOI: 10.9734/JPRI/2021/v33i41A32324

Editor(s):

(1) Dr. R. Deveswaran, M.S.Ramaiah University of Applied Sciences, India.

Reviewers:

(1) Chunmei Qi, Xuzhou Medical University, China.

(2) Noor Fatmawati Mokhtar, USM, Malaysia.

Complete Peer review History: <https://www.sdiarticle4.com/review-history/70646>

Original Research Article

Received 28 May 2021

Accepted 02 August 2021

Published 18 August 2021

ABSTRACT

Objective: The common side effects associated with cyclophosphamide administration are bone marrow suppression, exposure to infections, as well as cardiovascular complications, including sinus bradycardia, pericarditis, myocarditis, and type 1 heart problems. The present study was sought to investigate the effect of curcumin on modulating side effect of cyclophosphamide and the mechanisms involved.

Methods: This experimental study was carried out in the Department of Pharmacology, North Sumatra University during 2020. Thirty Wistar albino male rats, weighing 100 to 150 g (initial body weight); aged 85 to 100 days were selected for the study. After acclimatization for 14 days. Rats ($n = 30$) were pretreated with catechin (200 mg/kg, p.o.) alone, normal sample and different dose combination of curcumin (200, 400, 800 mg/kg, p.o.) in 10th day. The whole rats in each groups fed on 150 mg/KgBW of cyclophosphamide solution on days 11th to 15th of the trial. The heart was removed, blood was taken. Serum creatine kinase-MB (CK-MB) level was estimated by IFCC method and Troponin T (cTnI) level by ELISA method. The blood samples were collected and complete blood count were measured by cell counter. The statistical analysis was done by one way ANOVA followed by Tukey post hoc test, with coefficient interval of 95% ($\alpha = 0,05$).

*Corresponding author: E-mail: Addinmia@gmail.com;

Results: The results revealed that the CKMB and Troponin T levels decreased along with a dosage increase in the group with ethanol extract of white turmeric and an improvement in homeostasis and the histopathology of the liver of the rats. The impact of white turmeric is protective against cardiac cell damage of mice.

Keywords: Blood examination and histopathology; CKMB; curcuma zedoaria; curcumin, cyclophosphamide; troponin T.

1. INTRODUCTION

Cyclophosphamide is a very popular antineoplastic and immunosuppressant agent which comes under the class of oxazaphosphorine-alkylating agent. Its ability to kill tumor cell is mainly due to its DNA alkylation. Although it has tumor selectivity and a wide spectrum of clinical uses Cyclophosphamide is responsible to cause multiple organ toxicity Cyclophosphamide causes generation of two active metabolites such as phosphoramidate mustard and acrolein which can react with carboxyl (-C[O] OH), mercapto (-SH), amino (-NH₂), phosphate (-PO₃H₂), and hydroxyl (-OH) groups, and can form cross-links with DNA and proteins. and impaired secretion of heart lipoprotein lipase. Cyclophosphamide-induced alterations of lipid metabolism pathways in various conditions lead to myocardial lipid accumulation and lipotoxic cardiomyopathy [1]. Cyclophosphamide is a nitrogen mustard alkylating agent with potent antineoplastic, immunosuppressive, and immunomodulatory properties. Its use has long been established in cancer therapy and in pretransplant stem cell conditioning regimens. Cyclophosphamide's effect on both cell-mediated and humoral immunity has made it particularly appealing in the off-label treatment of several refractory autoimmune conditions [2].

Curcumin possess various pharmacological effects such as antioxidant, anti-inflammatory, anti-thrombotic, anti-apoptotic, and hepatoprotective activities. It has been reported that curcumin plays a pivotal role against skin, oral, lung, forestomach, colon, and prostate cancers. In some of the recent studies, it has been revealed that curcumin was found to be beneficial against isoproterenol, ischemia reperfusion, and doxorubicin-induced cardiotoxicity [3].

Turmeric (*Curcuma longa*), an Indian spice, is a yellow pigment that is used worldwide in cooking, cosmetics, dyes, and medicines. It is

worth nothing that turmeric is a frequently used food additive in Southeast Asia, which improves color and flavor of food preparations. Curcumin (chemical name: diferuloylmethane) is an active component of turmeric which has the capacity to interact with hundreds of molecular targets. Several studies have demonstrated the protective effects of curcumin against many chronic diseases, including various cancers, pulmonary disorders, and autoimmune diseases [4]. It has been shown to attenuate oxidative stress and to exert a cardioprotective effect owing to its lipid-lowering properties [5].

White turmeric contains bioactive compounds such as flavonoids, polyphenols, curcuminoid, terpenoids and essential oils. There are approximately 60 essential oil components and oleoresin in white turmeric with curzerenone, germacrone, camphor, curcumenol as the largest component [6].

Therefore, the aim of this study is to evaluate the cardio-protection effect of curcuma against cyclophosphamide induced cardiovascular complications.

2. METHODS

The materials utilized in this study include *Curcuma zedoaria*, *Camellia sinensis* Cycloid, Aquades, alpha-naphthol, HNO₃, RC(O)₂O, H₂SO₄, Ethanol (distilled), mercury (II) chloride, calcium chloride, calcium iodide, iodine, bismuth (III) nitrate, HCl, Pb(C₂H₃O₂)₂, FeCl₃, 10% formalin buffer, buffer Na₃C₆H₅O₇, isopropanol, hexane, 0.5% Na CMC, zinc powder, toluene, xylene, and dye (hematoxylin and eosin) [7].

The *Curcuma* rhizome obtained from UPT Materia Medica Batu, in East Java, cleaned and dried. Subsequently, the rhizomes were macerated with 96% ethanol, poured into a glass tube, and 75 pieces of polarised liquid were added. The tube was then sealed and left to stand 5 day in the absence of sunlight. This was followed by cleaning, pressing, and

maceration, with 96% ethanol. The rhizomes were then cut into 100 pieces, sealed, and left to stand for 2 days in the absence of sunlight. This was followed by filtration, evaporation using a rotary evaporator and drying at 40°C, to obtain thick extract [1].

Meanwhile, catechin leaves were washed and ground with a grinder. Subsequently, 50 grams of the powder obtained was then extracted for 3 hours with 250 ml water using soxlet and reflux apparatus with hot (45°C) water. The extract was then placed in a rotary evaporator, frozen at -20°C, and crushed to obtain powder. This powder was then combined with saline liquid (15 w/v), and intraperitoneally injected into mice at a dosage of 6 kg/bb. Only male group were used for this study. The mice were grouped into 6 different groups and placed in separate cages [8].

The CKMB and Troponin T serum were analysed in the Clinical laboratory, Faculty of Pharmacy, North Sumatra University. Serum

TnT levels were determined with the Enzym test (Boehringer Mannheim Corp) according to the manufacturer's instructions. This sandwich ELISA system is based on two mAbs, namely, a biotinylated cardiac TnT-specific capture antibody (M7) that binds to streptavidin-coated plastic tubes and a horseradish peroxidase-labeled detection antibody (1B10) that cross-reacts with skeletal muscle TnT. Because the assay has been developed for use in the human system, we had to ensure that it is also suitable for the murine system. This was achieved by comparing the reactivity of the mAbs with TnT from mice and humans with the use of Western blotting. Briefly, human tissue samples were obtained at autopsy from myocardial septum and intercostal muscles. Murine samples were obtained from whole hearts and from quadriceps muscles. Crude extracts were prepared by homogenizing 1 part of minced tissue in 15 parts (w/v) of Laemmli buffer under reducing conditions. The tissue extracts were then separated in 10% polyacrylamide-sodium dodecyl sulfate mini-gels (Hoefer Scientific

Table 1. Study design

| Group | Treatment |
|--|---|
| Normal sample | Distilled water and food |
| Negative population control | Distilled water and food Intraperitoneally Na CMC 0,5% once a day in 10 day Cyclophosphamid injection 150 mg/kgbb day 11 to day 15 |
| Positive population sample | Distilled water and food Intraperitoneally Catechin 200 mg/kgbb once a day in 10 day Cyclophosphamid injection 150 mg/kgbb day 11 to day 15 |
| Ethanol curcuma extract control 200 mg/kg bb | Distilled water and food Intraperitoneally curcumin ethanol extract 200 mg/kgbb once a day in 10 day Cyclophosphamid injection 150 mg/kgbb day 11 to day 15 |
| Ethanol curcuma extract control 400 mg/kg bb | Distilled water and food Intraperitoneally ethanol extract 400 mg/kg bb once a day in 10 day Cyclophosphamid injection 150 mg/kgbb day 11 to day 15 |
| Ethanol curcuma extract control 400 mg/kg bb | Distilled water and food Intraperitoneally ethanol extract 800 mg/kg bb once a day in 10 day Cyclophosphamid injection 150 mg/kgbb day 11 to day 15 |

Instruments) and electrophoretically transferred to BA 85 nitrocellulose sheets (Schleicher and Schuell). For immunostaining, the sheets were cut into strips, blocked with 1% bovine serum albumin in PBS containing 0.1% Tween 20 for 30 minutes, and incubated with either the biotinylated mAb M7 at concentrations ranging from 15 ng/mL to 600 µg/mL or the horseradish peroxidase-labeled mAb 1B10 at a concentration of 150 µg/mL. Strips with the mAb M7 were then incubated for 30 minutes with peroxidase-conjugated streptavidin (Dako) at a dilution of 1:10 000. Bound antibodies were detected by conversion of substrate (0.5 g/L, chloronaphthol) in the presence of 0.01% H₂O₂. Between each incubation step, the strips were washed several times with PBS containing 0.1% Tween 20 and, before reaction with substrate, with PBS alone [9].

Because a murine standard for the calibration of the TnT ELISA is not available, it was not possible to determine the absolute concentration of TnT in units of weight per volume. Therefore, the results had to be expressed as the relative TnT increase, which is defined as the ratio between the individual mouse TnT level and the upper normal level. The upper normal level was defined by the mean+SD value×1.96 of controls. Controls consisted of mice immunized with an irrelevant antigen, ie, skeletal muscle myosin. The ratio yielding absolute diagnostic specificity (no positive test results among mice without myocarditis) at the highest possible sensitivity level, ie, a relative increase of more than 2, was used as the cutoff value for TnT [9].

CKMB analysis was performed using the IFCC method. while Troponin T was analysed through ELISA test. Total CK activity was determined at 25°C with the Granutest 15 assay kit (Merck) according to the manufacturer's instructions. The upper normal value was 131 U/L (mean+SD value of nine untreated controls×1.96). Relative CK-MB isoenzyme activity was measured by fluorescent densitometry after electrophoretic separation of isoenzymes on agarose gels and incubation with substrate. Separation and visualization were performed according to the manufacturer's protocol (REP/EDC system, Helena Laboratories). CK-MB values were considered elevated if both the relative amount of CK-MB exceeded 4.5% of the total CK activity and the absolute CK-MB activity exceeded 12 U/L, as these values yielded absolute specificity at the highest possible sensitivity level [9].

The mice were first administered with cyclophosphamid, and curcumin extract was administered 2 hours later. Mice were anaesthetized (75 mg/kg, i.p.) and xylazine (8 mg/kg, i.p.) as anesthesia [1]. Incisions were made on the organs, and blood samples were collected in a glass tube containing liquid EDTA. Blood samples (4 mL) were collected by using a heparinized syringe (5 mL) from the inferior vena cava. The blood was divided into two portions. The first portion (1 mL) was transferred into tubes containing ethylene diamine tetra acetic acid (EDTA) for hematological analysis while the remaining blood was placed into plain tubes at ambient temperature for 30 min before centrifugation at 2000 rpm for 10 min to yield the serum for subsequent biochemical analysis. Lymphocyte, erythrocyte, thrombocyte and leucocyte count, and determine blood morphology using wright giemsa staining (5 drops of Giemsa in 1 ml of buffer phosphate) [7].

The mice hearts were harvested after mice were pronounced clinically dead, cleaned with 0.9% NaCl injection, and a part of each heart tissue was cut (0.5 x 0.5 x 0.5cm dimension for each part). Subsequently, the tissues were treated with 10% formalin, immersed in paraffin, cut into about 4µm per slide, and subjected to histopathology analysis using hematoxylin-eosin dye, in the Laboratory of Pharmacy, North Sumatra University [10]. Each blood cell type was measured in Mean ± SD with percentage (%) and analyzed with One Way ANOVA, followed by Tukey post hoc test, with coefficient interval of 95% ($\alpha = 0,05$).

Tables 1, 2, 3 and 4 show the results of troponin T assay, CKMB analysis, and blood cell type evaluation, respective.

According to the tables above, the CKMB and Troponin T levels are highest in the negative group, while the positive and the normal groups have almost the same values. Therefore, CKMB and Troponin T levels were concluded to decrease with increasing dosage of *curcumin zedoaria*.

The table above shows the leucocyte count decreases with increasing dosage of *Curcuma zedoaria* and is highest in the negative group. Meanwhile, the 0.5% Na CMC group's erythrocyte count was discovered to be the highest and to differ significantly from the, normal, and 400 mg/kgbb ethanol extract and

catechin groups ($p < 0.05$). In addition, the thrombocyte count for the catechin group differs significantly from the Na CMC 0.5% group ($p < 0.05$), while the lymphocyte count was discovered to differ significantly between each group ($p > 0.05$).

3. DISCUSSION

Curcumin can reduce atrophy of the myocardium as well as fibrosis of the cardiac cells. It also decreases the apoptotic myocytes occurring in mice treated with doxorubicin. Interestingly, curcumin is said to exhibit cardioprotective effect when co-administered with doxorubicin which may be contributed by autophagy. In fact, it has been hypothesized that repeated administration of doxorubicin reduce antioxidant level which increase the levels of cardiac biomarkers at the same time, giving the overall effect of inducing cardiomyopathy [11]. Overall, the mechanism of cardiotoxicity as induced by doxorubicin are several including oxidative damage level increase, increased in inflammation and apoptosis.

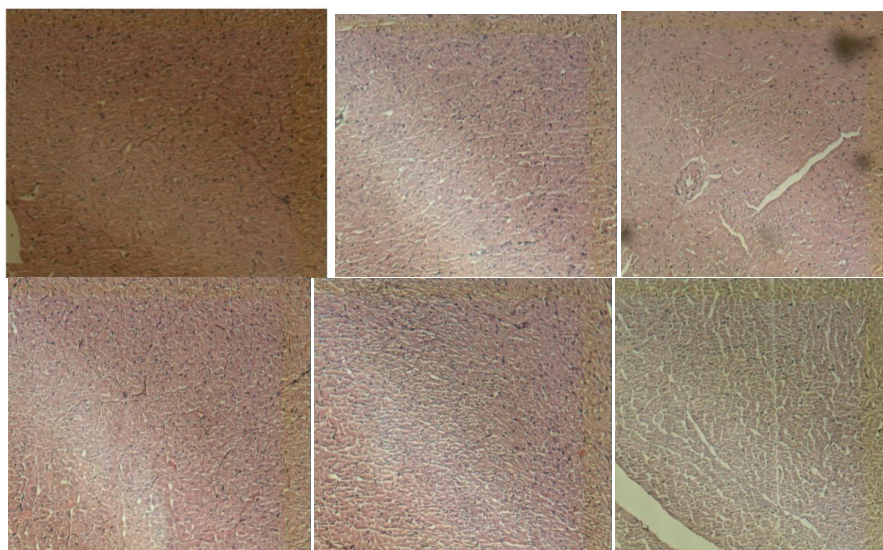
Cyclophosphamide is also an antineoplastic agent that may cause cardiac problem such as interstitial edema and hemorrhage, mainly attributed to the cause of oxidative stress. Cyclophosphamide induced oxidative stress results in abnormal cell death and these toxic metabolites lead to a direct damage of endothelial capillary blood vessels [12]. In a report, a group of rats treated with curcumin (100 mg/kg, p.o.) together with cyclophosphamide (30 mg/kg, i.p.) had low levels of damage in the myocardium based on histopathological and immunohistochemical properties as compared to rats administered with cyclophosphamide alone. Based on the study by Chakraborty et al (2017), the combination of oral curcumin (50 mg/kg, p.o.) and piperine (20 mg/kg, p.o.) confer better protection against cardiac toxicity that is induced cyclophosphamide (200 mg/kg, i.p.) as compared to treatment with curcumin (200 mg/kg, p.o.) alone [13]. In another study pretreatment of curcumin (200 mg/kg, p.o.) for 7 days before cisplatin (5 mg/kg, i.p.) exhibit cardioprotective effect based on histopathology, biochemical and cytokines changes when compared with cisplatin alone treated group [14].

Table 2. Interpretation of the Results of Troponin T Analysis with Cyclophosphamide Administration.

| Group | Result | Mean |
|--------------------------------|-------------|-----------------------|
| Normal Group | 0.065 pg/ml | 0.066 ± 0.003 pg/ml |
| | 0.07 pg/ml | |
| | 0.062 pg/ml | |
| | 0.067 pg/ml | |
| | 0.075 pg/ml | |
| Catechin or positive group | 0.07 pg/ml | 0.0675 ± 0.006 pg/ml |
| | 0.064 pg/ml | |
| | 0.061 pg/ml | |
| Negative group | 0.848 pg/ml | 0.7615 ± 0.273 pg/ml |
| | 0.449 pg/ml | |
| | 1.036 pg/ml | |
| | 0.533 pg/ml | |
| Ethanol extract of 200 mg/kgbb | 0.174 pg/ml | 0.1642 ± 0.027 pg/ml |
| | 0.197 pg/ml | |
| | 0.135 pg/ml | |
| | 0.151 pg/ml | |
| Ethanol extract of 400 mg/kgbb | 0.083 pg/ml | 0.1077 ± 0.0166 pg/ml |
| | 0.113 pg/ml | |
| | 0.117 pg/ml | |
| | 0.118 pg/ml | |
| Ethanol extract of 800 mg/kgbb | 0.091 pg/ml | 0.0987 ± 0.0142 pg/ml |
| | 0.107 pg/ml | |
| | 0.114 pg/ml | |
| | 0.083 pg/ml | |

Table 3. Interpretation of the results of CKMB analysis with cyclophosphamide administration

| No | Group | CKMB Mean \pm SD |
|----|--------------------------------|-------------------------|
| 1 | Normal Group | 354.0 \pm 81.0 kg/bb |
| 2 | Catechin or positive group | 389.0 \pm 102.5 kg/bb |
| 3 | Negative group | 843.0 \pm 140.0 kg/bb |
| 4 | Ethanol extract of 200 mg/kgbb | 600.0 \pm 37.0 kg/bb |
| 5 | Ethanol extract of 400 mg/kgbb | 595.0 \pm 157. kg/bb |
| 6 | Ethanol extract of 800 mg/kgbb | 572.0 \pm 61.0 kg/bb |

**Fig. 1. Interpretation of Histopathology Analysis in Mice Heart**

Results highlighted that there was no remarkable difference between all group control mice heart histological sections ($p < 0.05$)

The mice in the negative control group (Na CMC 0.5%) were discovered to have the highest CKMB values compared to other groups, and this enzyme decreased in each group, with increasing dosage of *Curcuma zedoaria*. However, the group with the highest dosage, 800 mg/kg bb had lower CKMB level, compared to the normal group. This study therefore shows *Curcuma zedoaria* has cardiac protection against cyclophosphamide induced cardiac complication in mice.

This study shows administering curcumin at dosage of 800 mg/kg bb or higher possibly balances the blood cell count, as well as CKMB and Troponin T level and reduce local Inflammation. *Curcuma zedoaria* is commonly known as “zedoary” and “white turmeric” in English and “er-jyur” in Chinese. It is native to northeast India and Indonesia but widely cultivated in subtropical regions including India, Southeast Asia, Thailand, Indonesia, Japan, and China [15]. Zedoary rhizome looks like

ginger from the outside (wrinkled gray, ash-colored) and like turmeric from the inside (brownish-red-yellow). It has a less intense aroma that can be rated between turmeric and mango. In addition, the rhizome powder of *C. zedoaria* is used for culinary purposes because of its unique smell, but has a very bitter and pungent taste, causing many people to substitute it with ginger.

Sharma et al. (2011) proved that *Curcuma longa* and curcumin stabilize the cell membrane and restore various blood parameters. The infected rats cotreated with curcumin showed increased WBCs value, PCV%, and monocyte cells due to immunostimulating activity of curcumin [16]. The effect of curcumin on hematological parameters in schistosoma mansoni-infected mice demonstrated slight improvement in RBCs, Hb%, PCV, and MCHC value compared to infected group [17].

Table 4 Tukey Analysis HSD for Each Blood Cell Type

| No | Keterangan | Leukocyte Mean ± SD | Erythrocyte Mean ± SD | Thrombocyte Mean± SD | Lymphocyte Mean ± SD |
|----|--------------------------------|------------------------|-----------------------------|---------------------------------|-------------------------------|
| 1 | Normal Group | 0.98 ± 0.26#c | 4.90 ± 0.26#c | 5.00 ± 1.00#c | 58.67 ± 23.46## ^u |
| 2 | Catechin or positive group | 1.17 ± 0.,54*c | 5.43 ± 0.03*c | 52.33 ± 3.51*c | 39.00 ± 2.00** ^u |
| 3 | group 0.5% CMC Na | 9.91 ± 1.39ab | 7.60 ± 0.24ab | 660.27 ± 294.27ab | 46.33 ± 2.52*# |
| 4 | Ethanol extract of 200 mg/kgbb | 5.83 ± 1.02abc | 6.32 ± 0.24*## ^u | 349.67 ± 157.39*## ^u | 58.33 ± 15.82*## ^u |
| 5 | Ethanol extract of 400 mg/kgbb | 2.71 ± 0.91*#c | 6.58 ± 0.28a## ^u | 16.00 ± 2.00*#c | 32.67 ± 5.13*## ^u |
| 6 | Kelompok EEKP 800 mg/kgbb | 1.40 ± 0.23*#c | 6.27 ± 0.24*## ^u | 28.50 ± 2.78*#c | 49.33 ± 1.53*## ^u |

In this study, the leukocytes count was discovered to reduce with increasing dose of *Curcuma zedoaria*, and this value was highest in the negative control group (Na-CMC 0.5%). Meanwhile, there was no significant difference among the lymphocytes count of each group, indicating the occurrence of acute inflammation of the liver due to elevated leukocytes. However, this was not accompanied by elevated lymphocytes, as a marker of chronic active inflammation. The groups administered with the ethanol extract of *Curcuma zedoaria* had similar leukocyte counts, but this value reduces with increasing dose. The treatment group that was given the ethanol extract of *Curcuma zedoaria* had almost the same number of leukocytes, but the group with the higher dose had fewer leukocytes. This is in line with a study conducted by Wardhani et, al (2020) Which found that *Curcuma zedoaria* had a protective effect against the white blood cells of mice exposed to CuSO₄ [18].

4. CONCLUSION

The results of this study also showed an improvement in the histopathology of the ethanolic extract of white turmeric at a dose of 800 mg /kgbb, matching the results of the catechin extract, and the normal group. Several studies have reported the pro-oxidant and oxidative stress properties of cyclophosphamide, leading to antioxidant activity and increased lipid peroxidation in several mice tissues.. For obtaining the therapeutic dosage, it is best to utilize a more diverse dose of white turmeric in future studies.

CONSENT

It is not applicable.

ETHICAL APPROVAL

Experiments were reviewed by the Ethics Committee, Prima University of Biomedicine, Medan, Indonesia and approved with the decision number 1271012S in January 2021.

COMPETING INTERESTS

Authors have declared that no competing interests exist.

REFERENCES

1. Chakraborty M, Kamath JV, Bhattacharjee A. Pharmacodynamic interaction of green

tea extract with hydrochlorothiazide against cyclophosphamide-induced myocardial damage. *Toxicol Int.* 2014;21: 196-202.

2. Baba J, Watanabe S, Saida Y, et al. Depletion of radio-resistant regulatory T cells enhances antitumor immunity during recovery from lymphopenia. *Blood.* 2012;120:2417-2427. *CIENCE B.* 2015;16(9):780-787.

3. Correa F, Buelna-Chontal M, Hernández-Reséndiz S, García-Niño WR, Roldán FJ, Soto V, et al. Curcumin maintains cardiac and mitochondrial function in chronic kidney disease. *Free Radic Biol Med.* 2013;61:119-29.

4. Kunnumakkara AB, Bordoloi D, Padmavathi G, Monisha J, Roy NK, Prasad S, Aggarwal BB. Curcumin, the golden nutraceutical: multitargeting for multiple chronic diseases. *Br J Pharmacol;* 2016. DOI:10.1111/bph.1362.

5. Pulido-Moran M, Moreno-Fernandez J, Ramirez-Tortosa C, Ramirez-Tortosa M. Curcumin and health. *Molecules.* 2016;21: 264

6. Singh P, Singh S, Kapoor IPS, Singh G, Isidorov, V, Szczepaniak L. Chemical composition and antioxidant activities of essential oil and oleoresins from *Curcuma zedoaria* rhizomes, part-74. *Food Bioscience.* 2013;3:42-4.

7. Ongko NX, Chiunan L, Ginting CN. Effect of White Turmeric Rhizome Extract (*Curcuma zedoaria*) on Testis Histology of Male Wistar Rat', *Am. Sci. Res. J. Eng. Technol. Sci.* 2019;55(1):69-74.

8. Yunarto N, Elya B, Konadi L. Potency of ethylacetate fraction of gambir leaves extract (Uncariagambir Roxb.) as antihyperlipidemia. *The Indonesian Pharmaceutical Journal.* 2015;5:1-10

9. Alkedaide A, Soliman MM, Ibrahim ZS. Carbonated soft drinks alter hepatic cytochrome P450 isoform expression in Wistar rats. *Biomed. Reports.* 2016;5(5):607-612.

10. Sharma S, Khan V, Najmi AK, Alam O, Haque SE. Prophylactic treatment with icariin prevents isoproterenol-induced myocardial oxidative stress via nuclear factor-like 2 activation, *Pharmacogn. Mag.* 2018;14:227.

11. Katamura M, Iwai-Kanai E, Nakaoka M, Okawa Y, Ariyoshi M, Mita Y, et al. Curcumin attenuates doxorubicin-

- induced cardiotoxicity by inducing autophagy via the regulation of JNK phosphorylation. *Journal of Clinical and Experimental Cardiology*. 2014;5(9): 1000337.
12. Avci H, Epikmen ET, Ipek E, Tunca R, Birincioglu S, Aksit H, et al. Protective effects of silymarin and curcumin on cyclophosphamide-induced cardiotoxicity. *Experimental and Toxicologic Pathology*. 2017;69:317-27.
 13. Bahadır A, Ceyhan A, Gergin OO, Yalçın B, Ulger M, Ozyazgan TM, et al. Protective effects of curcumin and beta-carotene on cisplatin-induced cardiotoxicity: An experimental rat model. *Anatolian Journal of Cardiology*. 2018;19: 213.
 14. Chakraborty M, Bhattacharjee A, Kamath JV. Cardioprotective effect of curcumin and piperine combination against cyclophosphamide-induced cardiotoxicity. *Indian J pharmacol*. 2017;49:65-70.
 15. Zhou L, Zhang K, Li J, Cui X, Wang A, et al. Inhibition of vascular endothelial growth factor-mediated angiogenesis involved in reproductive toxicity induced by sesquiterpenoids of *Curcuma zedoaria* in rats. *Reprod. Toxicol*. 2013;37: 62–69.
 16. Sharma V, Sharma C, Sharma S. Influence of curcuma longa and curcumin on blood profile in mice subjected to aflatoxin B1. *Int JmPharm Sci Res*. 2011;2(7): 1740.
 17. Mahmoud EA. Effect of curcumin on hematological, biochemical and antioxidant parameters in *Schistosoma mansoni* infected mice. *Int J Sci*. 2013;2(2013–03):1–14.
 18. Wardhani FM, Chiuman L, Novalinda Ginting C, Ginting SF. Role of cystatin-C as serum biomarkers in predicting glomerular function associated with copper-induced acute kidney injury. *MKB*. 2020;52(1):16–21.

© 2021 Amrullah et al.; This is an Open Access article distributed under the terms of the Creative Commons Attribution License (<http://creativecommons.org/licenses/by/4.0>), which permits unrestricted use, distribution, and reproduction in any medium, provided the original work is properly cited.

Peer-review history:
The peer review history for this paper can be accessed here:
<https://www.sdiarticle4.com/review-history/70646>