



The Formation of Mucociliary Insufficiency in the Bronches on the Role of Respiratory Viral Infection

Dilorom Kamarovna Ishankulova^{a*}

^a *Department of Internal Medicine, Faculty of Pediatrics, Samarkand State Medical Institute, Samarkand, Republic of Uzbekistan.*

Author's contribution

The sole author designed, analysed, interpreted and prepared the manuscript.

Article Information

DOI: 10.9734/JPRI/2022/v34i34A36139

Open Peer Review History:

This journal follows the Advanced Open Peer Review policy. Identity of the Reviewers, Editor(s) and additional Reviewers, peer review comments, different versions of the manuscript, comments of the editors, etc are available here: <https://www.sdiarticle5.com/review-history/86243>

Received 15 February 2022

Accepted 21 April 2022

Published 23 April 2022

Original Research Article

ABSTRACT

Background: The spectral composition and frequency of viral infections have been studied in frequently and long-term patients with respiratory diseases (PRI), as well as their role in the formation of mucociliary insufficiency. The role of immunosuppressive conditions and mixed infection is emphasized for the occurrence of complications.

Methods: Examined 29 patients with prolonged acute bronchitis (APB); 36 patients with recurrent bronchitis (RB) and 48 patients with chronic bronchitis (CB). The patients underwent general clinical studies according to a single plan adopted in the therapeutic department, as well as virological and immunological studies.

Results: The study of the spectral composition of viral infections in often long-term patients with bronchopulmonary pathology shows a high incidence of active ($f = 0.93$) and associated viral infections ($f = 0.79$), which largely determines the nature of the inflammatory process. The pathogenic role of certain viruses, such as influenza A, RS virus, adeno- and coronavirus ($f = 0.84$; 0.78 ; 0.77 ; 0.64), and their associations during the inflammatory process is undoubted. The frequency of respiratory syncytial viral (RS-viral) infection, which is characterized by damage to the deepest parts of the respiratory tract, is high ($f = 0.78$).

Conclusion: Comparative clinical and virological characteristics of patients made it possible to reveal the undoubted value of persistent in ABZ and RB ($f = 0.55$; 0.40), as well as chronic in RB ($f = 0.15$) viral infection, being one of the important causes of recurrent and protracted course of OB, as well as in the formation of altered bronchial reactivity (IRB) in them. A clinical case of a patient with influenza pneumonia is presented.

[#]Associate professor

*Corresponding author: E-mail: dilorom.ishankulova@gmail.com;

Keywords: Acute protracted bronchitis; recurrent bronchitis; chronic bronchitis; altered bronchial reactivity; viral infections; mucociliary insufficiency.

1. INTRODUCTION

Viral infections (influenza, rhinoviruses) are not limited to the defeat of the large bronchi, but also spread to the small respiratory tract, the inflammation of which can last up to several weeks. From the first minutes after infection, the influenza virus penetrates the alveolar cells, which further ensures the ascending nature of the influenza infection. Even in the incubation period, viremia occurs, continuing during the manifest stage of the disease. We have established the value of inapparent forms of the course of influenza, which do not involve the possibility of transition to manifest diseases [1].

The complex of inflammation associated with a viral infection includes the classic triad - alteration, exudation and proliferation in combination with a sharp change in the permeability of cell membranes, impaired microcirculation of blood and lymph, a decrease in the functional activity of cells and organs with damage to them. All these changes cause dysfunction of internal organs [2]. So, RS-, adenovirus, influenza and parainfluenza viruses have morphological abnormalities of the epithelium of the respiratory tract, which lead to violations of its main functions: integrating (active production of regulatory peptides, protection of submucosal structures), neuro-regulatory (irritation of irritant receptors located on the surface of the epithelium bronchi) and immune (quantitative and qualitative changes in specific and nonspecific defense).

When studying the state of local immunity of the upper respiratory tract in frequently ill children during the period of remission was revealed with significant dysbiotinososis of the mucous membranes of the respiratory tract. A significant decrease in lysozyme and immunoglobulin A in saliva was established. The number of phagocytic neutrophils was increased, while the phagocytic index was decreased. Scientists note that, if in infrequently ill children, an increase in the synthesis of immunoglobulins occurs on 3-4 days of illness, then in those who are often ill, only on 14-15 days. When examining patients with frequent relapses of the inflammatory process against the background of chronic obstructive pulmonary disease (COPD), their characteristic feature was the suppression of the phagocytic activity of peripheral blood neutrophils

and alveolar macrophages. It was noted that inhibition of local phagocytic activity and indicators of phagocytosis of alveolar macrophages was much more pronounced than inhibition of general phagocytic activity [3, 4, 5].

Currently, the possibility of a destructive effect of respiratory viruses on the alveoli-interalveolar septa has been proven, i.e. their role in the formation of pulmonary emphysema. Moreover, defective viruses, as well as their individual components, which for a long time remain in the epithelial cells of the bronchi and alveolar macrophages and monocytes that phagocytosed them, also have proteolytic activity [6, 7].

Persistent respiratory viruses in the distal bronchi stimulate the proteolytic activity of alveolar macrophages and neutrophils, this is facilitated by the activation of the kallikrein-kinin system and the fibrinolytic activity of the blood [2].

Oxidants are another equally important factor in pathogenesis. Virus-activated macrophages and other phagocytic cells secrete oxidants (singlet oxygen, oxygen radicals - superoxide anion radical (O₂⁻), etc.). The effect of oxidants on the pathogenesis of inflammation in the bronchi is diverse. So they increase the secretion of mucus of the bronchial glands, worsen the function of the ciliated epithelium of the bronchi; reduce the activity of β -adrenergic receptors and, conversely, increase the activity of cholinergic structures; stimulate the synthesis of thromboxanes and leukotrienes, which leads to an increase in the content in the lungs of substances with contractile, vasoactive and procoagulant effects. A high concentration of oxidants disrupts the dynamic balance with antioxidants (ceruloplasmin, superoxide dismutase, tocopherols). When the pathogenic action of oxidants is realized, not only defective, but also normal epithelial cells are damaged [8, 9].

The combination of the pathogenic action of respiratory viruses and oxidants creates and increases "bald spots" on the bronchial mucosa, as a springboard for adhesion of opportunistic bacteria (hemolytic streptococcus, etc.), and an initially nested inflammatory process of the bronchial mucosa develops - endobronchitis, which gradually becomes diffuse. At the same time, inflammatory edema, hypertrophy of the

mucous glands, viscous secretion, increased tone of bronchial muscles, their sensitization to bronchospastic reactions - in their totality, violate the drainage function of the bronchi and are factors (mechanisms) of labile obstruction in a certain part of patients [2,10].

With the development of a viral infection of the upper respiratory tract, the loss of the ciliated epithelium leads to a decrease in mucociliary clearance.

Penetrating into the epithelial cells of the bronchial mucosa, the virus disrupts the metabolism in them and leads to the death of epithelial cells; viral infection of the respiratory tract contributes to sensitization of the respiratory tract, even in previously healthy subjects. MCC slows down until it stops completely. The recovery period for MCC after the disappearance of symptoms of the disease is 2-3 months [11].

Chronization of the inflammatory process is characterized by prolonged release of the respiratory tract from virus-specific antigens (AH), which often lasts up to 1.5 months from the onset of viral infection. With repeated influenza infection that occurs more often (after 1-1.5 years), bronchoscopy reveals bilateral catarrhal endobronchitis and hyperinjection of the bronchial mucosa [1, 12].

1.1 The Relevance of the Research

Changes in the morphology of the bronchial mucosa or the physical properties of bronchial secretions, due to the effect of various, mainly exogenous pathogenic factors, lead to a slowdown in mucus excretion and airway clearance or mucociliary clearance (MCC). The role of viruses in the development of mucociliary insufficiency (MCI) in the bronchi remains one of the most pressing problems of pulmonology.

1.2 Purpose of the Research

To study the role of a respiratory viral infection in the formation of mucociliary insufficiency in "often and long-term ill" patients with colds.

2. MATERIALS

Examined 29 patients with prolonged acute bronchitis (APB); 36 patients with recurrent bronchitis (RB) and 48 patients with chronic bronchitis (CB). The patients underwent general clinical studies according to a single plan

adopted in the therapeutic department, as well as virological and immunological studies.

The study substrate was a set of materials from patients, including brush biopsy of the nasopharyngeal mucosa (Brn), brush biopsy of the bronchial mucosa (Brbr), bronchial lavage and bronchoalveolar lavage fluid (BAL). These materials were studied in order to identify viruses and viral hypertension. In addition, not only viral AH, but also "local" antiviral antibodies were detected in washes and BAL. The main material for the detection of humoral antibodies were paired or more sera of patients; sera collection intervals were 2 to 3 weeks.

2.1 Methods

A complex of methods was used to study various substrates from patients. Viral antigens (AG) were detected using ELISA, as well as by the method of immunofluorescence (MIF). Antiviral antibodies were detected using ELISA, conventional serological tests (HIR, CBR, GNR), as well as a neutralization reaction (RN). Specific antibodies of classes M and G were detected using ELISA. According to the indications, the patients underwent a bronchoscopic examination, with the sampling of material for microbiological, cytological and histomorphological studies. The absorption capacity of neutrophils and monocytes was assessed by the degree of capture of latex particles by them (I.V. Pokhodzei et al., 1989).

3. RESEARCH RESULTS

APB proceeded sluggishly, with a weakly expressed inflammatory reaction, RB - wave-like and was characterized by a change in the phases of active inflammation and relative clinical well-being. The majority of patients with OBZ noted the duration of their illness > 8 weeks ($f = 0.85$). The average duration of the active inflammation phase in RB was 3-5 ($f = 0.5$) and ≥ 8 weeks ($f = 0.5$). The number of active phases of inflammation during the year in RB patients was from 3 to 5. Most patients with CP noted the duration of the last exacerbation from 4 to 8 weeks ($f = 0.33$) and >12 weeks ($f = 0.44$). Also, the number of exacerbations ≥ 3 times a year was noted in the majority of patients (0.67). Active viral infection was detected in OBZ, in RB and CB with a frequency of 0.93; 0.82; 0.95, respectively. At the same time, the associations of viruses in these groups were determined with a significantly higher frequency ($f = 0.79$; 0.9; 0.88, respectively). Influenza type A viruses ($f =$

0.74; 0.61; 0.58, respectively), RS virus (f = 0.55; 0.78; 0.65, respectively), adenovirus (f = 0.77; 0.65; 0.41, respectively) and corona virus (f = 0.8; 0.9; 0.9, respectively). Somewhat less often - mycoplasma pneumonia (f = 0.4; 0.36; 0.35); influenza type B (f = 0.3; 0.11; 0.14). Persistent viral infection in the subgroup of patients with OBZ, RB and CB was detected in almost half of the patients (f = 0.45; 0.55; 0.66, respectively). The study of the spectrum of viruses among patients with persistent viral infection revealed a high frequency of prolongation (from 5 to 8 weeks or more) of influenza antigen A (f = 0.36; 0.40; 0.6 respectively), adenovirus (f = 0.45; 0.36; 0.5, respectively) and RS-virus (f = 0.37; 0.28; 0.5, respectively) [1].

So, with a moderate decrease in the rate of MCC, as a rule, there were moderate damage to the epithelium of the bronchi and moderately pronounced signs of catarrhal endobronchitis. Severe disorders of the regional MCC were more often accompanied by significant changes in the bronchial mucosa, according to endoscopic examination (f = 0.56) and electron microscopy (f = 0.62), and less often by moderate changes (f = 0.43 and 0.37, respectively). Along with this, according to electron microscopy, in the overwhelming majority of patients with a moderate degree of MCI, moderate (f = 0.75) and pronounced (f = 0.60) signs of damage to the bronchial mucosa were recorded with a significant decrease in the function of the

mucociliary systems. During bronchoscopy in patients with chronic bronchitis, marked bilateral endobronchitis (f = 0.75), hypersecretion, hyperinjection, foamy compartment from the bronchi were noted; at later stages in the aspirate - casts of small bronchi (f = 0.65). The cellular composition of BALF was characterized by a significant decrease in the number of alveolar macrophages (2-3 times) compared with the norm; frequent (f = 0.65) and long-term up to (1.5-2 months) detection of influenza AH (H3, N2) in macrophages was also noted.

3.1 Case from Practice

A 5-year-old boy was admitted to the hospital due to rapidly progressive respiratory failure, with symptoms of fever – 39.2 ° C, rhinorrhea and cough, respiratory rate 30 breaths / min, oxygen saturation 90% and weakened breathing in the left lung. Pneumonia was diagnosed on a chest x-ray showing an infiltrative shadow in the left inferior field of the lung, atelectasis of the entire left lung, and deviation of the trachea to the left (Fig. 1). The left upper and lower bronchi were blocked by dense mucous casts. The patient was intubated and underwent bronchoscopy. (Fig.2, 3). Immediately after removing the bronchial casts (Fig. 4), his respiratory condition improved and after 2 days he was extubated. The polymerase chain reaction was positive for influenza A (H₁N₁pdm09) [4].

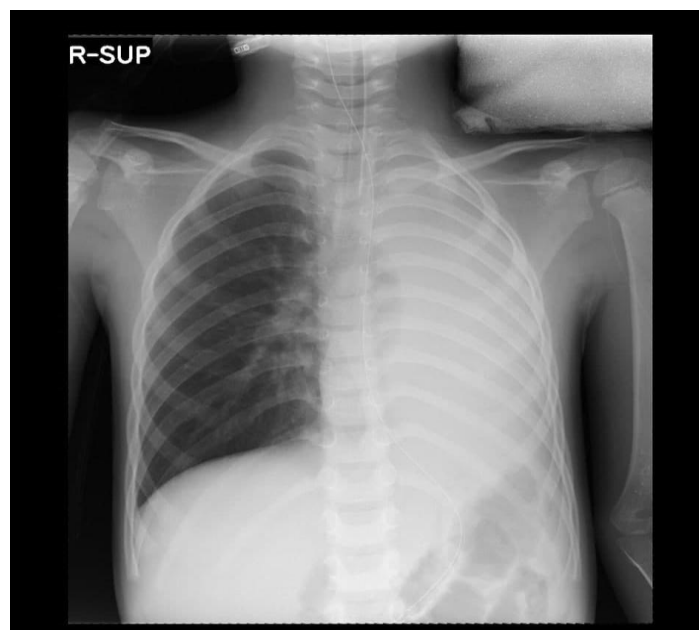


Fig. 1. Result of chest X-ray before bronchoscopy: an infiltrative shadow in the left inferior field of the lung, atelectasis of the entire left lung, and deviation of the trachea to the left

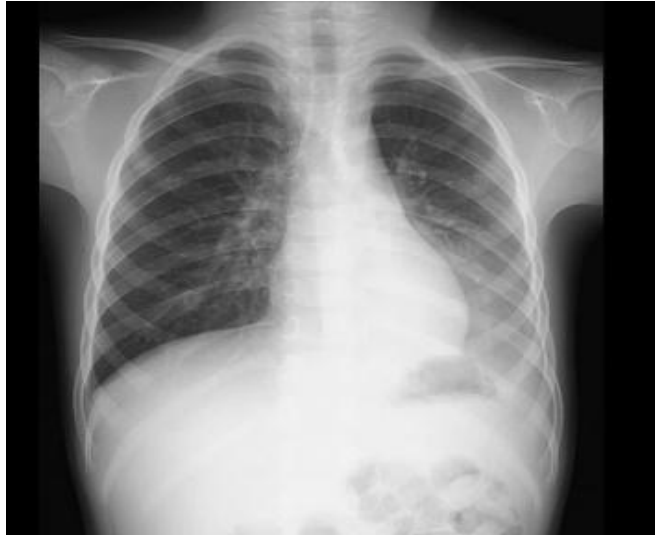

Fig. 2. Result of chest X-ray after bronchoscopy: The pulmonary pattern has returned to normal

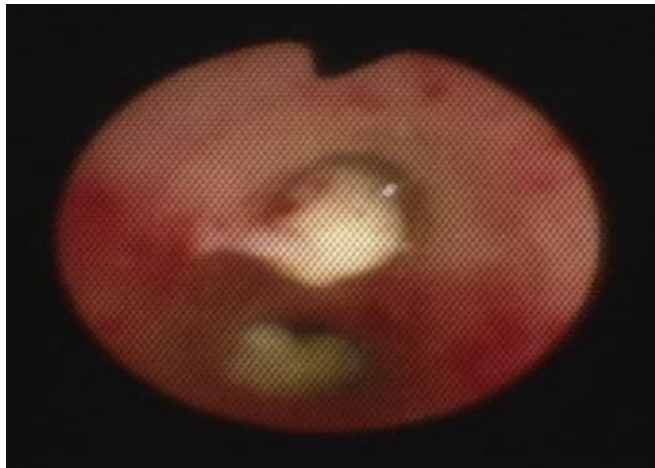


Fig. 3. Removal of dense mucous casts using bronchoscopy

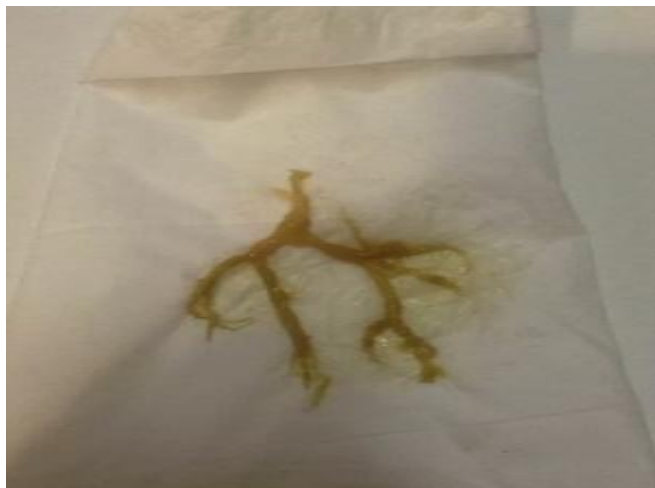

Fig. 4. Bronchial casts

4. CONCLUSIONS

Thus, patients with acute protracted and recurrent bronchitis, as well as chronic bronchitis with initial manifestations of obstruction constitute a significant contingent of "often and long-term illnesses"; their active inflammatory process is often complicated by altered bronchial reactivity. For "BHB" respiratory infections complicated by IRI, active respiratory viral infection and, in particular, its associated forms are characteristic. Comparative clinical and viral characteristics of patients made it possible to reveal the undoubted importance of persistent and chronic viral infection, being one of the important reasons for the recurrent and protracted course of OB, as well as in the formation of altered bronchial reactivity (IRB) in them. Correlation between MCC disorders and the severity of IRD signs, according to bronchofibroscopy and electron microscopy, mainly in the exacerbation phase, indicates that MCI and the inflammatory process in the bronchial tree have a mutually aggravating effect.

CONSENT

As per international standard or university standard, patients' written consent has been collected and preserved by the author(s).

ETHICAL APPROVAL

It is not applicable.

COMPETING INTERESTS

Author has declared that no competing interests exist.

REFERENCES

1. Ishankulova DK. Unidirectionality of etiopathogenetic changes in patients with acute and chronic bronchitis as a reality of chronic inflammation in the bronchi. *Journal of cardiorespiratory research. Innovative progress in internal medicine research. Materials of the international scientific-practical conference.* S.2021;23-24.
2. Chronic bronchitis and obstructive pulmonary disease / Ed. Kokosova A.N. - St. Petersburg: Publishing House "Lan". 2002;288 (World of Medicine).
3. Ishankulova DK. On the persistence of treatment at various stages with an active complex effect on infectious, allergic and immunological links in the pathogenesis of patients with chronic bronchitis. *Fundamental Science in Modern Medicine. Abstracts in the Proceedings of the International Scientific and Practical Online Conference; to the 90th anniversary of Sam GosMI S.* 2020;202-203.
4. Michiko Yoshida Plastic Bronchitis Associated with Influenza. *The Journal of Pediatrics.* 2021;335.
5. Sharipov RK, Akhmedova MM, Rasulova NA, Erbutayeva LT. Interaction of correction of lipid peroxidation disorders with oxibral. *International Journal of Current Research and Review.* 2021; 13(3):2-5.
6. Nasirova AA, Kurbanova ZP, Ishankulova DK, Juraev SO. Features Of Immunological Indicators In Patients With Chronic Obstructive Lung Disease And Bronchial Asthma. *Solid State Technology Volume: 63 Issue: 6 Publication Year. 2020;6873-6880 (Scopus).*
7. Ibatova SHM, Mamatkulova FKH, Rakhmonov YA, Shukurova DB, Kodirova MM. Assessment of the effectiveness of treatment of rachit in children by gas-liquid chromatography. *International Journal of Current Research and Review.* 2021;13(6):64-66.
8. Nasirova A, Babamuradova Z, Abdinova E, Nosirova D. Immunodiagnosis of chronic obstructive pulmonary disease and associated bronchial asthma. *Annals of the Romanian Society for Cell Biology.* 2021;13090-13097.
9. Abdullaev S, Shonazarov I, Rahmanov U, Toirov A. Problems of Diagnostics, Prevention and Surgical Tactics of Treatment of Adhesive-Intestinal Obstruction. *Annals of the Romanian Society for Cell Biology.* 2021;2289-2294.
10. Ruziyeva AA, Ishankulova DK, Nizomov BU. Verification of dyspnea according to external respiratory function in patients with bronchial asthma. *International journal on orange technologies.* 2021;03:30-33.
11. Bakhronov SS, TA, OS, Bobomuratov Melieva MA. Clinical Significance of T-31c Polymorphism of Il-1 β Gene in Recurrent Bronchitis in Children. *Annals of the Romanian Society for Cell Biology.* 2021; 4742-4748.
12. Ibatova SM, Mamatkulova FK, Abdukadirova NB, Rakhmonov YA, Kodirova MM. Risk factors for the

development of broncho-obstructive of Current Research and Review.
syndrome in children. International Journal 2020;12(23):3-6.

© 2022 *Ishankulova*; This is an Open Access article distributed under the terms of the Creative Commons Attribution License (<http://creativecommons.org/licenses/by/4.0>), which permits unrestricted use, distribution, and reproduction in any medium, provided the original work is properly cited.

Peer-review history:

*The peer review history for this paper can be accessed here:
<https://www.sdiarticle5.com/review-history/86243>*