



Effect of the Dexamethasone and the Difenihidramiana on the Degranulation of the Eosinophilic Granular Cell of Tilapia

Luis Alberto Romano^{1*} and Virgínia Fonseca Pedrosa¹

¹Laboratory of Immunology and Pathology of Aquatic Organisms, Institute of Oceanography, Federal University of Rio Grande, Rio Grande, Brazil.

Authors' contributions

This work was carried out in collaboration between both authors. Author LAR managed the analysis of EGCs, writing and research of literature. Author VFP worked with the histopathological processing of the samples. Both authors read and approved the final manuscript.

Article Information

DOI: 10.9734/AJRIZ/2021/v4i230110

Editor(s):

(1) Dr. Layla Omran Elmajdoub, Misurata University, Libya.

Reviewers:

(1) Charles Obinwanne Okoye, University of Nigeria, Nigeria.

(2) Shyamal Kumar Paul, Noakhali Science and Technology University, Bangladesh.

Complete Peer review History: <http://www.sdiarticle4.com/review-history/68145>

Original Research Article

Received 27 February 2021

Accepted 04 May 2021

Published 07 May 2021

ABSTRACT

The aim of this study was to determine the relationship between EGC degranulation in fish injected with formalin-killed *Escherichia coli* and the effect of dexamethasone, diphenhydramine supplied separately and before formalin-killed *E. coli*. We performed a quantitative analysis of the number of cell granules and demonstrated that: compared to the EGCs of animals, the injection of dead *E. coli* with formalin generated degranulation of the EGC, while the administration of dexamethasone alone did not show significant differences with control group animals. The administration of diphenhydramine alone did not show significant differences neither with the animals of the dexamethasone treated group nor with those of the control group. When dexamethasone was administered one hour before the *E. coli* injection, degranulation was apparently inhibited and the number of granules did not show significant differences either with the animals in the control group or with those treated with dexamethasone. Finally, when this group was compared with the group of animals that were only injected with *E. coli*, the differences were statistically significant. However, when diphenhydramine was administered one hour before *E. coli* injection, a critical inhibition of EGC degranulation was evidenced, with a marked increase in the number of granules.

*Corresponding author: Email: dcluis@yahoo.com, luisalbertoromano0@gmail.com;

All this seems to show that dexamethasone can partially inhibit the release of substances that participate in the inflammatory process. Diphenhydramine, a recognized antihistamine, inhibited degranulation of EGCs. These results suggest that EGC can release histamine like mammalian mast cells.

Keywords: Degranulation of EGC; dexamethasone; diphenhydramine; tilapia.

1. INTRODUCTION

Eosinophilic granule cells (EGC) are mononuclear cells that contain abundant and prominent eosinophilic granules. The histochemical characteristics of EGCs and their participation in tissue reactions in various pathologies have led to the suggestion that EGCs are analogous to mammalian mast cells [1-4]. In a previous work we have examined the distribution of EGCs in *Prochilodus platencis*, their staining qualities and we analyzed the heterogeneity of granular metachromasia, which, as in mammalian mast cells, may depend on the expression of cellular proteoglycan [5,6]. The distribution around vascular structures, its relationship with infection by parasites and its ability to stimulate granulocyte migration suggest that this cell actively participates in the inflammatory response, and furthermore, EGCs seem to be closely related to the defense mechanisms of the fishes. The reason for this is that cytoplasmic degranulation can be observed after inoculation of some substances (eg, *Aeromonas salmonicida* and *Vibrio anguillarum* toxins, substance P, capsaicin) [7,8].

Dexamethasone is a glucocorticoid that causes various metabolic effects. One known effect is impaired immune response [9]. Dexamethasone was used primarily in human and veterinary medicine for its anti-inflammatory effects.

Histamine is obtained from three main sources, histidine decarboxylation in tissues, histidine decarboxylation by bacteria in the gut, and diet. Most of the histamine remains as granules in the cytoplasm of mammalian mast cells and possibly in fish EGCs. The types of histamine receptors that have been described are: H1 and H2 receptors that participate in the regulation of the immune system and in the control of histamine feedback, the H3 receptors that participate in the modulation of cholinergic neurotransmission in mammals [10]. Diphenhydramine hydrochloride is an antihistamine medication. These drugs are generally an H1 receptor antagonist. In human medicine, diphenhydramine is used to alleviate the symptoms of various allergic conditions [11].

The objective of this study was to determine the relationship between the degranulation of the EGCs in fish injected with killed *Escherichia coli* with formalin and the effect of dexamethasone, diphenhydramine applied individually and previously applied the dead *Escherichia coli* with formalin. Some authors show the inhibitory effect of cortisol on EGC degranulation in tilapia [12], but the effect of diphenhydramine on EGC degranulation has not been studied in fish.

2. MATERIALS AND METHODS

We studied 30 male Nile tilapia, *Oreochromis niloticus* (Linnaeus, 1759), weight 550.89 + 5.2 g, acclimatized for approximately one month on the 3000-L plastic track. During this time, the water temperature was 24°C, with continuous aeration and systematic recirculation through a biological filter, and the tank was supplied with a constant flow of dechlorinated water. The photoperiod was from 6:00 a.m. to 6:00 p.m., provided by a fluorescent light (daylight; 350 lux). The fish were fed daily with dry pellets (38% protein; Ganave Argentina). The animals were separated into six groups of five fish each group:

Group I: Killed *Escherichia coli* with formalin (strain: AMI 1239) (1 mg / fish) was injected by the intraperitoneal (IP) route. Group II: Dexamethasone (Sidus, Argentina) 30 mg / kg of fish weight were injected for IP. Group III: Diphenhydramine (Elea, Argentina) 20 mg / kg of fish weight were injected for IP. Group IV: Dexamethasone 30 mg / kg of body weight was injected into fish intraperitoneally 1 hour before injecting *Escherichia coli*. Group V: 20 mg / kg of diphenhydramine were injected into fish intraperitoneally 1 hour before injecting them with *Escherichia coli*. Group VI: Control group, the fish were injected with distilled water.

Animals in each group were sacrificed 2 hours after the end of the experiment, deeply anesthetized and injected with absolute ethanol into the swim bladder to avoid degranulation of EGC during necropsy and swim bladder preparation. The stretched swim bladder preparations were according to [13,14]. The

swim bladders were removed with clamps stretched and fixed to a vinyl board previously cut to the appropriate dimensions. The board and tissue were immersed in absolute ethanol for fixation for 10 minutes. Fixed tissue was stained with Giemsa's solution for 6 to 12 h. The sample was then washed and dehydrated with acetone to remove excess stain and dehydrate the sample. The preparation was transferred to xylene for cleaning, cut (20 x 20 mm) and mounted with Canada balsam [15].

The quantitative analysis by light microscopy, number of granules per cells (G / C), was carried out according to the methods [16,17,18]. Statistical analysis: The results were expressed as mean (\pm S.E). Statistical analysis was performed using Student's t test; $P < 0.05$ was considered significant.

3. RESULTS AND DISCUSSION

EGC granules were stained with Giemsa stain. Most of the EGCs of the swim bladder were located around the blood vessels (Fig. 1).

In the group I animal (injected with *Escherichia coli* killed with formalin) the number of granules per cells (GC) was 39.7 ± 6.9 , these animals the EGC showed fusion of adjacent granules and the formation of cytoplasmic vacuoles was considered as evidence of degranulation (Fig. 2).

In the group II animal (treated with dexamethasone) the GC was 80.5 ± 7.2 . In the group III animal (treated with diphenhydramine) the GC was 82.7 ± 5.4 . In the latter two groups, EGCs showed Giemsa metachromatically stained granules and did not show fusion of adjacent granules or vacuole formation. In the group IV animal (treated with dexamethasone and previously injected with killed *Escherichia coli* with formalin) the GC was 83.8 ± 3.1 . In the group V animal (treated with diphenhydramine and previously injected with dead *Escherichia coli* with formalin) the GC is 160.2 ± 6.1 . In these last two groups, the EGC showed an increase in the number of granules with affinity staining, similar groups II and III (Fig. 3). In the animal of group VI (control group) the fish were injected with distilled water, the GC is 79.5 ± 7.2 .

The swim bladder is a hydrostatic organ that contains gas. The lumen of the swim bladder is lined with a simple epithelium, below which are smooth muscle cells. A layer of loose connective tissue separates these epithelial and muscle

layers from an outer layer of fibrous connective tissue that has smooth muscle cells, capillaries, and EGCs [19]. In contrast to the roles played by monocytes, macrophages, neutrophils, and lymphocytes, the roles of EGCs in teleosts are areas of controversy [20,21]. Functionally, EGCs show great similarity to mammalian mast cells. Acute tissue damage causes degranulation of EGCs and the release of inflammatory mediators, whereas an increase in the number of these cells is often found in chronically inflamed tissues [22]. Other authors have shown the involvement of EGC's in the inflammatory process in the hybrid tambacu, injecting Carrageenin and thioglycollate in the swim bladder and evaluated the exudate cells [23], which differs from our work, as we evaluate the entire fabric of the swim bladder.

In this study we carried out a quantitative analysis of the number of granules per cell (GC) in different situations, stimulating the degranulation of EGC, injected intraperitoneally *dead E. coli* with formalin and our results suggest that, compared to EGC of control animals (group VI) (79.5 ± 7.2 GC), the injection of killed *E. coli* with formalin (group I) generated a marked degranulation of the cells (39.7 ± 6.9 GC), while the administration Dexamethasone alone (group II) did not show statistically significant differences with the animals of the control group (80.5 ± 7.2 GC). In the same way, the administration of diphenhydramine alone (group III) (82.7 ± 5.4 GC) did not show statistically significant differences neither with the animals of the treated group nor with those of the control. When dexamethasone was administered one hour before the injection of killed *E. coli* with formalin (group IV), degranulation was apparently inhibited (83.8 ± 3.1 GC) and the number of granules did not show significant differences even with the animals. of the control group. nor with those treated with dexamethasone. Finally, when this group was compared with the group of animals that were only injected with *E. coli*, the differences were statistically significant. However, when diphenhydramine was administered one hour before the injection of dead *E. coli* with formalin (group V), a critical inhibition of EGC degranulation was evidenced, with a marked increase in the number of granules in the cell cytoplasm (160 ± 6.1 GC). This seems to show that dexamethasone can partially inhibit the release of substances that participate in the inflammatory process. Diphenhydramine, a recognized antihistamine drug, inhibited EGC degranulation.

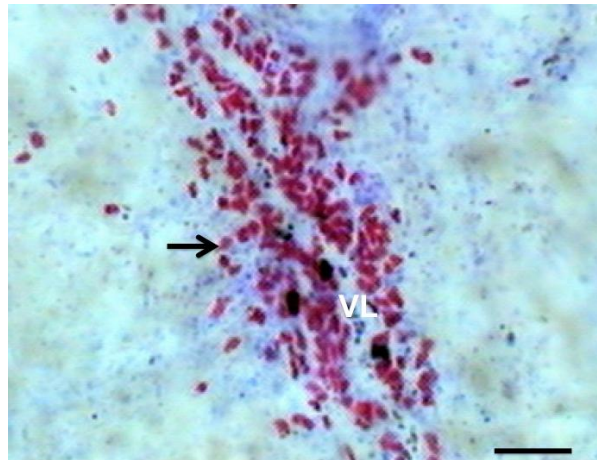


Fig. 1. Swim bladder stained with Giemsa. The EGCs located around a blood vessel (arrows). VL: Vascular lumen. Giemsa. Bar: 100 μ m

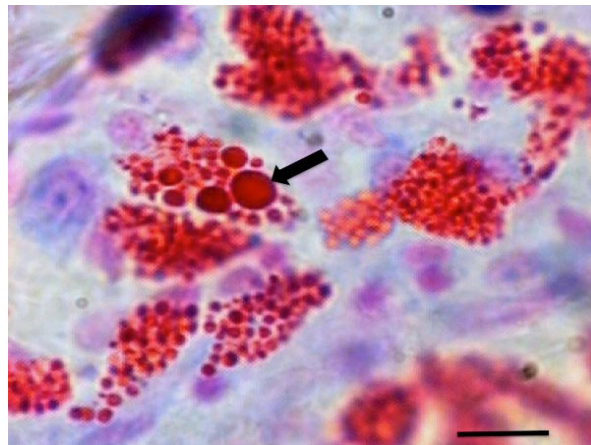


Fig. 2. EGCs showed fusion of adjacent granules and formation of cytoplasmic vacuoles (arrows). Giemsa. Bar: 10 μ m

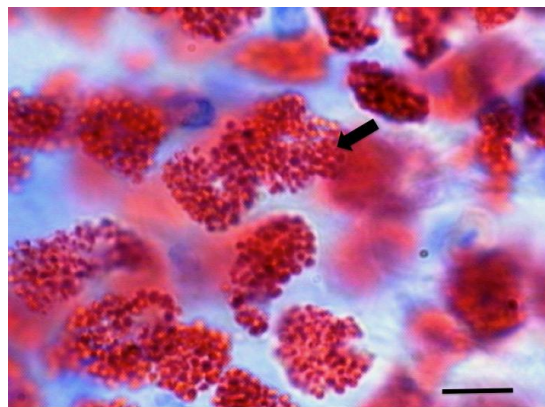


Fig. 3. EGCs showed a higher number granules (arrows), in group V animals (treated with diphenhydramine and before injected with formalin-killed *Escherichia coli*) Giemsa. Bar: 100 μ m

In the inflammatory process, histamine remains the first substance considered in any discussion of the natural mediators of this process. Historically, histamine is widespread in tissues and, in particular, is associated with granules of mammalian mast cells [24,25]. To date, the classification of histamine receptors has been based on a rigorous classical pharmacological analysis and, thus far, the classification of the three histamine receptors that have been defined by this process (i.e., the H1, H2 and H3) have not been added due to more recent molecular biological approaches [26,27,28]. Some authors state that intestinal EGCs of rainbow trout show low tissue concentrations of histamine could be measured in the posterior gut, the authors described in general, there is a very good correlation between histamine present in cells and the tissue concentration and conclude what the EGCs be considered as homologous with mammalian eosinophils and not with mast cells [29]. However, many authors found similar characteristics between mammalian mast cell and EGCs of the fishes. Although fishes EGCs are considered mammalian's mast cell analogues from their staining affinity and responses to noxious agents [30].

However, it seems that there is a similarity between EGC and mammalian mast cells, some authors who have already studied these cells in depth in tilapia, define them as fish mast cells (fMC) [31]. These authors conclude that fish vascular endothelial cells express some neutrophil addition molecules that alter stimulation with various substances similar to mammalian mast cells. This work suggests that an antihistamine such as diphenhydramine inhibits or decreases EGC degranulation. This suggests that EGC, among other substances that participate in the inflammatory process, can release histamine like mammalian mast cells.

In mammals, different populations of mast cells have been demonstrated. Mast cells in various stages of maturation were observed in these populations. In sensitization and activation experiments with IgE-deficient mice, high levels of histamine were tested in serum and also evidenced that tidular mastocytes undergo great degranulation, even in the absence of IgE [32].

Mast cell maturation is related to the acquisition of several receptors that activate the release of mediators such as b-hexosaminidase and histamine at levels that are comparable to those achieved in mature mast cells [33]. As

demonstrated in the study cited above, the histamine-releasing activity of mammalian mast cells is already at early maturation levels, indicating that histamine production and release is a typical mast cell activity. With this in mind, if EGC are considered equivalent to mammalian mast cells, the histamine production of this cell must be considered as its own.

Diphenhydramine is a first-generation antihistamine that is used in a variety of conditions to treat and prevent various histamine-induced pathologies.

Regarding the mechanism of action, diphenhydramine acts mainly by antagonizing the H1 receptor. The H1 receptor is found in smooth muscles, vascular endothelial cells, the gastrointestinal tract, heart tissue, cells of the immune system, and neurons of the nervous system. When the H1 receptor is stimulated in these tissues, it produces a wide variety of actions including increased vascular permeability, promotion of vasodilation that causes redness, decreased conduction time of the atrioventricular node, and eosinophilic chemotaxis that promotes allergic immune response. Since diphenhydramine is a first-generation antihistamine, it readily crosses the blood-brain barrier and reverse agonizes CNS H1 receptors. Diphenhydramine is metabolized by the liver through CYP450. It is excreted unchanged in the urine and has a half-life of 3.4-9.2 hours. Its peak time, serum is 2 hours [34,35].

4. CONCLUSION

In summary, at work we saw that between the animals of the control group (GVI) and those injected with *E. coli* (GI), there is no significant difference. There are no significant differences between the animals belonging to those treated with dexamethasone (GII) and diphenhydramine (GIII). There is a significant difference between the animals that were given *E. coli* and subsequently treated with dexamethasone (GIV) and the animals that were given *E. coli* and subsequently treated with diphenhydramine (GV), ($P < 0.05$). These data suggest that diphenhydramine inhibits the release of EGC granules, so it can be inferred that these granules contain histamine.

ETHICAL APPROVAL

Animal Ethic committee approval has been taken to carry out this study.

ACKNOWLEDGEMENTS

This study was supported by the research funds from MCT/CNPq- Project #301245/2016-09 MCT/CNPq/CT- Agronegocio/MPA Public Notice 036/2009 Project #308013/2009-3, Coordenação de Aperfeiçoamento de Pessoal de Nível Superior (CAPES), and Ministério da Pesca e Aquicultura (MPA).

COMPETING INTERESTS

Authors have declared that no competing interests exist.

REFERENCES

1. Ellis AE. Eosinophilic granular cells (EGC) and histamine responses to *Aeromonas salmonicida* toxin in rainbow trout. Developmental and Comparative Immunology. 1985;9:251-260.
2. Powell MD, Wright GM, Burka JF. Degranulation of eosinophilic granule cells induced by capsaicin and substance P in the intestine of the rainbow trout (*Oncorhynchus mykiss* Walbaum). Cell and Tissue research. 1991;266:469-74.
3. Powell MD, Briand HA, Wright GM, Burka JE. Rainbow trout (*Oncorhynchus mykiss* Walbaum) intestinal eosinophilic granule cell (EGC) response to *Aeromonas salmonicida* and *Vibrio anguillarum* extracellular products. Fish & Shellfish Immunology. 1993;3:279-89.
4. Reite OB. Mast cells/Eosinophilic granule cells of salmonids: staining properties and responses for noxious agents. Fish & Shellfish Immunology. 1997;7:567-84.
5. da Silva EZ, Jamur MC, Oliver C. Mast cell function: a new vision of an old cell. J Histochem Cytochem. 2014;62(10):698-738. DOI: 10.1369/0022155414545334. Epub 2014 Jul 25.
6. Méndez-Enríquez E, Hallgren J. Mast Cells and Their Progenitors in Allergic Asthma. Front Immunol. 2019;10:821. DOI: 10.3389/fimmu.2019.00821
7. Vallejo AN, Ellis AL. Ultrastructural study of the response of eosinophil granule cells to *Aeromonas salmonicida* extracellular products and histamine liberators in rainbow trout *Salmo gairdneri* Richardson. Developmental and Comparative Immunology. 1989;13:133-48.
8. Reite OB. Mast cell/eosinophilic granule cells of teleostean fish: a review focusing of staining properties and functional responses. Fish & Shellfish Immunology. 1988;8:489-513.
9. Giles AJ, Hutchinson MND, Sonnemann HM, Jung J, Fecci PE, Ratnam NM, Zhang W, Song H, Bailey R, Davis D, Reid CM, Park DM, Gilbert MR. Dexamethasone-induced immunosuppression: mechanisms and implications for immunotherapy. J Immunother Cancer. 2018 Jun 11;6(1):51. DOI: 10.1186/s40425-018-0371-5.
10. Parsons ME, Ganellin CR. Histamine and its receptors. Br J Pharmacol. 2006;147 Suppl 1(Suppl 1):S127-35. DOI: 10.1038/sj.bjp.0706440.
11. Treherne JM, Young JM. Temperature dependence of the kinetics of the binding of 3H-(1)-N-methyl-4-methyl diphenhydramine to the histamine H1-receptor: comparison with the kinetics of 3H-mepyramine. Br J Pharmacol. 1988;94:811-822.
12. Matsuyama T, Kurogi J, Iida T. Inhibitory effect of cortisol on the degranulation of eosinophilic granular cells in tilapia. Fish Pathology. 1999;32:91-95.
13. Reite OB, Eveson Ø. Mast cells in the swim bladder of Atlantic salmon *Salmo salar*. Histochemical and responses to compound 48/80 and formalin-inactivated *Aeromonas salmonicida*. Disease of Aquatic Organisms. 1994;20:95-100.
14. Zahí PA, Nowak Jr. A rapid technique for demonstrating mast cells in mouse skin. Stain Technology. 1949;24:185-199.
15. Matsuyama T, Iida T. Degranulation of eosinophilic granular cells with possible involvement in neutrophil migration to site of inflammation in tilapia. Dev Comp Immunol. 1999;23:451-57.
16. Weibel ER. Stereological Methods: Practical Methods for Biological Morphometry. II Vol. London: Academic Press; 1979.
17. Christiansen HE, Brodsky SR, Cabrera ME. Aplicación de una técnica morfométrica en la determinación de la fecundidad en invertebrados marinos. Phycis. 1973;84:121-135.
18. Romano LA, Stella I, Inserra F, Ferder L. High Correlation in Renal Tissue Between Computed Image Analysis and Classical Morphometric Analysis. J. of Histotechnology. 1996;19:121-123.
19. Morrison CM, Fitzsimmons K, Wright Jr. JR. Atlas of Tilapia Histology. Baton

- Rouge, Louisiana, United States: The World Aquaculture Society; 2006.
20. Reite OB, Evensen O. Inflammatory cells of teleostean fish: a review focusing on mast cells/eosinophilic granule cells and rodlet cells. *Fish Shellfish Immunol.* 2006; 20(2):192-208.
DOI: 10.1016/j.fsi.2005.01.012.
 21. Santos D, Falcão A, Luzio A, Fontainhas-Fernandes A, Monteiro SM. Neuroendocrine and eosinophilic granule cells in the gills of Tilapia, *Oreochromis niloticus*: Effects of waterborne copper exposure. *Arch Environ Contam Toxicol.* 2015;69(4):566-76.
DOI: 10.1007/s00244-015-0170-7.
 22. Schmale MC, Vicha D, Cacal SM. Degranulation of eosinophilic granule cells in neurofibromas and gastrointestinal tract in the bicolor damselfish. *Fish Shellfish Immunol.* 2004;17(1):53-63.
DOI: 10.1016/j.fsi.2003.12.002.
 23. Martins ML, Myiazaki DMY, Tavares-Dias M, Fenerick Jr. J, Onaka EM, Bozzo FR, Fujimoto RY, Moraes FR. Characterization of the acute inflammatory response in the hybrid tambacu (*Piaractus mesopotamicus* male × *Colossoma macropomum* female) (Osteichthyes). *Braz. J. Biol.* 2009;69(3): 957-962.
 24. Riley JF, West GB. Mast Cell and histamine. *J. Pathol Bacteriol.* 1955; 69:269-282.
 25. Uvñas B. Histamine release in mast cells. *N.Y Acad. Sci.* 1963;104:190-211.
 26. Schwartz JC, Arrang JM, Garbarg M, Traiffort E. Histamine. In: Bloom FE, Kupfer DJ, eds. *Psychopharmacology: The Fourth Generation of progress.* New York: Raven; 1995.
 27. Hill SJ. Distribution, properties and functional characteristics of three classes of histamine receptor. *Pharmacol. Rev.* 1990;42:45-83.
 28. Leurs R, Smit MJ, Timmerman, H. Molecular pharmacological aspects of histamine receptors. *Pharmacol. Ther.* 1995;66:413-463.
 29. Sire MF, Vernier JM. Partial characterization of eosinophilic granule cells (EGCs) and identification of mast cells of the intestinal lamina propria in rainbow trout (*Oncorhynchus mykiss*). Biochemical and cytochemical study. *Biol Cell.* 1995;85:35-41.
 30. Matsuyama T, Iida T. In Vitro degranulation of tilapia eosinophilic granular cells and its effect on neutrophil migration. *Fish Pathology.* 2000;35:125-129.
 31. Matsuyama T, Iida T. Tilapia mast cell lysates enhance neutrophil adhesion to cultured vascular endothelial cells. *Fish Shellfish Immunol.* 2002;13:243-250.
 32. Castells, MC. Biología celular y molecular del mastocito. *Rev. Esp. Alergol Inmunol Clin.* 1997;6:327-339.
 33. Hill SJ, Ganellin CR, Timmerman H, Schwartz JC, Shankley NP, Young JM, Schuanack W, Levi R, Haas HL. International Union of Pharmacology. XIII. Classification of Histamine Receptors. *Pharmacological Reviews.* 1997;49:253-258.
 34. Mauser PJ, Kreutner W, Egan RW, Chapman RW. Selective inhibition of peripheral histamine responses by loratadine and terfenadine. *Eur J Pharmacol.* 1990;182(1):125-9.
DOI: 10.1016/0014-2999(90)90500-6.
 35. Sicari V, Zabbo CP. Diphenhydramine. 2020 Jul 13. In: StatPearls [Internet]. Treasure Island (FL): StatPearls Publishing; 2021.

© 2021 Romano and Pedrosa; This is an Open Access article distributed under the terms of the Creative Commons Attribution License (<http://creativecommons.org/licenses/by/4.0>), which permits unrestricted use, distribution, and reproduction in any medium, provided the original work is properly cited.

Peer-review history:
The peer review history for this paper can be accessed here:
<http://www.sdiarticle4.com/review-history/68145>