

Rare Case of Sars COV2 Virus (COVID 19) Associated Intra Myocardial Hematoma and Role of Diagnostic Imaging

Naresh Sen ^{a*} and Sonal Tanwar ^b

^a Consultant Cardiologist Pushpanjali Hospital, Rewari, Haryana VG University, India.
^b VG University, India.

Authors' contributions

This work was carried out in collaboration between both authors. Both authors read and approved the final manuscript.

Article Information

DOI: 10.9734/CA/2022/v11i430201

Open Peer Review History:

This journal follows the Advanced Open Peer Review policy. Identity of the Reviewers, Editor(s) and additional Reviewers, peer review comments, different versions of the manuscript, comments of the editors, etc are available here: <https://www.sdiarticle5.com/review-history/85777>

Case Study

**Received 12 March 2022
Accepted 20 April 2022
Published 25 April 2022**

ABSTRACT

SARS Cov2 infection is a pandemic declared by WHO in early month of 2020 as corona virus disease (COVID 19) which was diagnosed first in Wuhan, China in December 2019. During first wave of COVID 19 we faced with severe acute respiratory insufficiency and respiratory failure with common symptoms of high-grade fever, shortness of breath and loss of sensations but later on we accessed the different symptoms to related with multi systems of human body. Cardiac emergencies or cardiovascular morbidities with mortality were accessed across the globe during COVID 19 pandemic era. Data revealed that SARS Cov2 affected on heart by both direct or indirect pathway which leads to acute myocarditis, myocardial injury/infarct, heart failure, thrombosis and arrhythmias. Here we are presenting a rare case as hematoma in myocardium called as intramyocardial dissecting hematoma. Non-invasive diagnostic tools to prevent mortality in cardiology field and avoid further complication.

Keywords: SARS Cov2; intramyocardial hematoma; echocardiogram; cardiac MRI.

1. INTRODUCTION

SARS Cov2 infection affect the heart by the both direct and indirect way and resulting as endothelial dysfunction, platelets aggregation, thrombosis, acute myocardial injury and infarct followed by arrhythmias as per reported cases in last 2 years [1-2]. As per COVID 19 induced severe myocarditis and injury can cause myocardial rupture and make responsible for thrombus or hematoma in mural myocardium called as intramyocardial hematoma (IMH). Intramyocardial dissecting hematoma (IDH) is an unfavorable rare form of myocardial rupture which can lead to acute myocardial injury or infarction [3].

2. CASE REPORT

A 45-year-old north Indian male with grade 1 central obesity, smoker, euglycemic, normotensive was admitted to the emergency department with complaints of chest pain, general malaise last 2 days. He reported himself as 5 days fever history with RT PCR positive for SARS Cov2 infection. At initial presentation, his vital signs were 109 bpm pulse rate, 129/83 mm Hg blood pressure, 90% oxygen saturation, and 99°F of axillary temperature with random blood sugar 112 mg/dl. On examination jugular venous pressure was in normal range, no cyanosis and lymphadenopathy, cardiovascular examination revealed normal first and second heart sounds, without added heart sounds and murmurs. Fine basal rales were heard in both lungs. As per emergency protocol electrocardiogram was taken which revealed sinus tachycardia and ST elevation in V3, V4, V5 and V6 with T wave inversion (Fig. 1). 2D echocardiogram was performed immediately which showed dyskinctic apex and akinetic apical septum and apical anterior wall with moderate left ventricular systolic dysfunction on the basis of left ventricular ejection fraction around 35-40%.(Fig. 2) According to 4 chamber view of echo we accessed the thrombotic mass with pulsatile cavity at the apex of LV, subsequently color doppler showed no flow within that structure with systolic expansion. There was no evidence of trauma, no evidence of papillary muscle rupture and pericardial effusion. As per the lab data suggest slightly high value of troponin I as a cardiac bio-marker, raised D-dimer value, raised CRP level (78 mg/L) and IL-6 (212 pg/ml). HRCT chest revealed as high score 19 with bilateral SARS Cov2 infiltrations.

He was shifted to intensive coronary care unit with prompt conservative medical treatment of delayed acute coronary syndrome on antiplatelets with subcutaneous anticoagulant injection enoxaparin 0.6 ml, statin, ACE inhibitor, antianginal, anti-viral injection Remdesibir, monoclonal antibody injection Tocilizumab and injection paracetamol and pantoprazole with levosulpirid [4]. After shifting the ICCU we noticed that one episode of ventricular tachycardia which was reverted pharmacologically by injection lignocaine 2ml intravenously with the help of injection iv magnesium 2ml followed by low dose of amiodarone 8 hourly. ABG report was in normal limit but there was hypokalemia and low level of serum magnesium which were corrected timely in ICU.

Contrast echocardiogram was performed to diagnose and rule out of malignancy which revealed pulsatile thrombus with thin endocardium boundary with separate entity (Fig. 2B, C) and Cardiac MRI showed as confirmative diagnosis and slight extension of intramyocardial hematoma (Fig. 3). Coronary invasive angiogram was performed which revealed normal coronaries with mild left ventricular dysfunction (Fig. 4). Serial echocardiogram was performed three times in duration of 15 days in hospital and another three serial echocardiograms were performed with one-time Cardiac MRI for thrombus size reduction and improving left ventricular function during follow up of 6 months on oral new anticoagulant therapy with maintained INR. After 6 months of follow up patients became free from dyspnea and chest heaviness and final 2D Echocardiogram showed thick scarred in apical myocardium without any significant hematoma but jerky movement was accessed, however left ventricular systolic function became subnormal around LVEF -55%.

3. DISCUSSION

SARS Cov2 infection is a pandemic declared by WHO in early month of 2020 as corona virus disease (COVID 19) which was diagnosed first in Wuhan, China in December 2019. During first wave of COVID 19 we faced with severe acute respiratory insufficiency and respiratory failure with common symptoms of high-grade fever, shortness of breath and loss of sensations but later on we accessed the different symptoms to related with multi systems of human body. SARS Cov2 viral infection became responsible for multi systemic inflammation followed by multi organ failure [1-4].

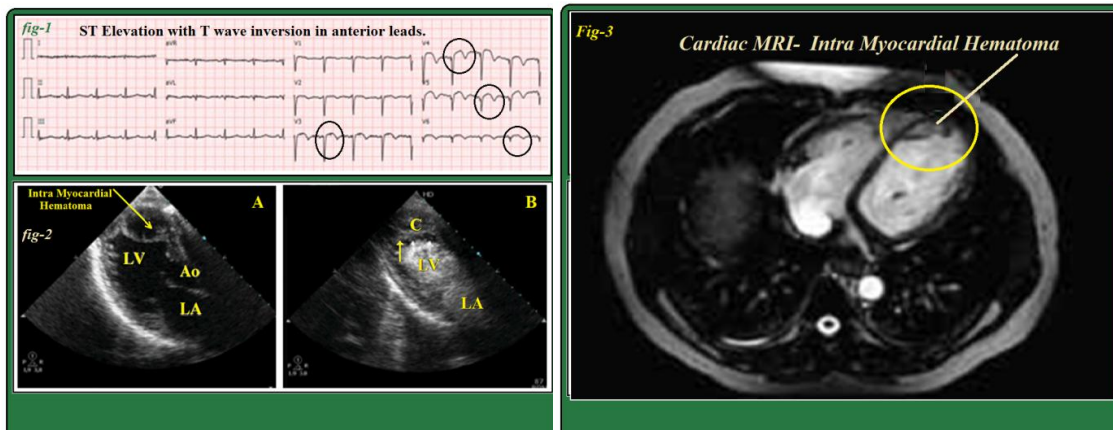


Fig. 1. ECG-ST elevation V3-V6 Fig. 2. Echo LV Apical intramyocardial hematoma A- 2D Echo, B- 2D Contrast Echo Fig. 3. Cardiac MRI- IMH

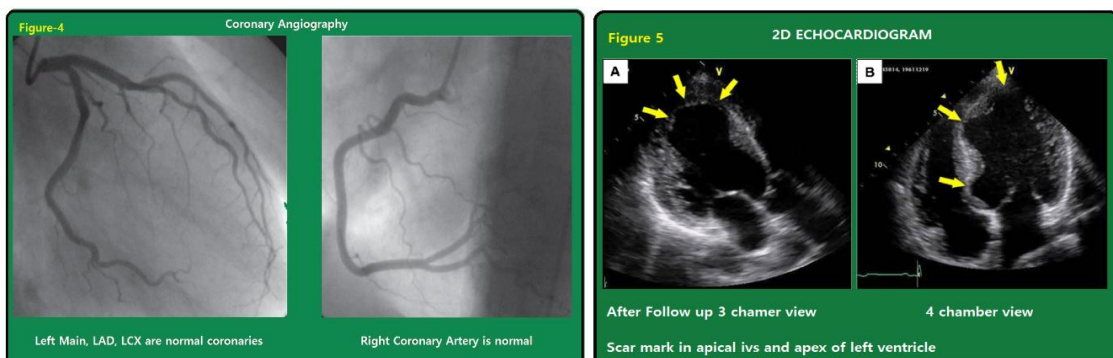


Fig. 4. Coronary Angiogram- normal coronary arteries Fig. 5. 2D Echo follow up after 6 months Scar present apex and apical septum of left ventricle

As per our specialty we are facing different kinds of cardiac emergencies in COVID 19 era since last 2 years like acute coronary syndrome, myocarditis, myocardial infarction, heart failure and arrhythmias [1-2]. Here we are presenting our rare case in form of unfavorable condition as intramyocardial hematoma in this young Indian fellow.

As simple as that SARS Cov2 enter to the body through lungs and attach with angiotensin converting enzyme ACE 2 receptor followed by cell entry and lysed of protein coating leading to start replications. More viral load affects the immune system and inflammatory process which may changes in the endothelium resulting as proinflammation, pro-proliferation and pro-fibrosis. Its effects on heart through microvascular and macrovascular changing way which resulting inflammation, endothelial changes cause acute myocarditis, injury and infarction without obstruction of coronary arteries [1-4]. Here, in this patient first myocarditis was

developed and after that increased permeability and spasm of myocardial vessels which lead to rupture and finally thrombus formation occurred. SARS Cov2 viral load is responsible for high thrombotic burden along with injury extension of spiral myocardial fibers creating a neo-cavitation limited by the myocardium cause regional ST segment elevation in ECG [4-5] and akinesia of apex and apical segment of septum and poor LV systolic function or reduced ejection fraction [5-6] On the basis of reality with strong mechanism of intramyocardial hemorrhage have no sufficient space to extend easily, that's why it may dissect the myocardium or may expand by rupturing adjacent myocardial fibers of closer structures which might be cause of life-threatening complication like ventricular arrhythmia and sudden cardiac death [3-8]. Data revealed that diagnosis of intramyocardial dissecting hematoma has commonly been cleared during surgery or post-mortem and some time by echocardiography or cardiac MRI at advanced cardiac center [7-8].

Fortunately, in this case we could make diagnosed early and became happy to save the life of this patient with the helping of previous literatures or studies has been published regarding intramyocardial hematoma [2,3,9]. Routinely in cardiac practice of acute coronary syndrome presenting as chest pain with ST segment elevation, shifting to Cath lab, coronary angiogram followed by stenting or medication and cardiac bypass surgery depend on indications. But in normal coronaries during angiogram and missed the diagnosis by the routine 2D echocardiography as LV apical thrombus, apical hypertrophy, ventricular trabeculations and small apical aneurysm [4,8]. After that mostly physician's advice is being notice about medical management. But in reality, early diagnosis is mandatory by advance 2D myocardial contrast echocardiogram followed by Cardiac MRI if possible, to pick the intramyocardial hematoma. Finally, we can avoid the major adverse consequences of IMH like large dissection, life threatening arrhythmias and death with the help of advance contrast echocardiogram and 2D serial echo imaging and cardiac MRI [7,8]. Intramyocardial hematoma is a serious condition which is required to diagnose promptly on the basis of 2D echocardiogram followed by cardiac MRI and these diagnostic imaging tools could be role model to reduce the mortality and hospital burden [9]. We can save the life of this type of patients in cardiac emergencies by prompt diagnosis with standard medical management or timebound cardiac surgery if large extended with pseudoaneurysm or extensive dissecting intramyocardial hematoma on compromised hemodynamic level [10,11].

4. CONCLUSION

Intramyocardial thrombus or hematoma is rare but unfavorable cardiac emergency which might be horrible without prompt diagnosis and management. 2D Contrast echocardiogram with serial imaging and Cardiac MRI are useful non-invasive tools for early diagnosis to avoid further extension or dissection with expansion and to prevent further complication and mortality.

CONSENT

As per international standard or university standard, patients' written consent has been collected and preserved by the author(s).

ETHICAL APPROVAL

As per international standard or university standard written ethical approval has been collected and preserved by the author(s).

ACKNOWLEDGEMENT

We would like to give special thanks to all editorial members and superiors for their valuable guidance.

COMPETING INTERESTS

Author has declared that no competing interests exist.

REFERENCES

1. Farshidfar F, Koleini N, Ardehali H. Cardiovascular complications of COVID-19. *JCI Insight*. 2021 Jul 8;6(13):e148980. DOI: 10.1172/jci.insight.148980. PMID: 34061779; PMCID: PMC8410051.
2. Luo J, Zhu X, Jian J, Chen X, Yin K. Cardiovascular disease in patients with COVID-19: evidence from cardiovascular pathology to treatment. *Acta BiochimBiophys Sin* (Shanghai). 2021;53(3):273-282. DOI: 10.1093/abbs/gmaa176. PMID: 33428706; PMCID: PMC7929476.
3. Allende NG, Santos R, Sokn FJ, Merino SA, Accastello GM, Medina JC, Isquierdo IN, Rapallo CA. Unusual presentations of cardiac rupture during COVID-19 pandemic. *Echocardiography*. 2021;38(3):469-472. DOI: 10.1111/echo.15006. Epub 2021 Feb 18. PMID: 33599346; PMCID: PMC8014092.
4. Hendren NS, Drazner MH, Bozkurt B, Cooper LT Jr. Description and Proposed Management of the Acute COVID-19 Cardiovascular Syndrome. *Circulation*. 2020;141(23):1903-1914. DOI: 10.1161/CIRCULATIONAHA.120.047349. Epub 2020 Apr 16. PMID: 32297796; PMCID: PMC7314493.
5. Lechner I, Reindl M, Tiller C, Holzknecht M, Troger F, Fink P, Mayr A, Klug G, Bauer A, Metzler B, Reinstadler SJ. Impact

- of COVID-19 pandemic restrictions on ST-elevation myocardial infarction: a cardiac magnetic resonance imaging study. *Eur Heart J*. 2021 Oct 11;ehab621. DOI: 10.1093/eurheartj/ehab621. Epub ahead of print. PMID: 34632491; PMCID: PMC8524546.
6. De Stefano D, Parillo M, Garipoli A, Beomonte Zobel B. Imaging findings in a case of myo-pericarditis associated with SARS CoV-2 disease. *J Cardiol Cases*. 2021;24(5):210-214. DOI: 10.1016/j.jccase.2021.07.006. Epub 2021 Aug 3. PMID: 34367382; PMCID: PMC8328569.
 7. Rezaei-Kalantari K, Saedi S, Alizadeasl A, Naghshbandi M. Left ventricular intramyocardial dissection after myocardial infarction. *Echocardiography*. 2020;37(12):2160-2162. DOI: 10.1111/echo.14843. Epub 2020 Nov 5. PMID: 33155293.
 8. Vargas-Barrón J, Roldán FJ, Romero-Cárdenas A, Molina-Carrión M, Vázquez-Antona CA, Zabalgoitia M, Martínez Rios MA, Pérez JE. Dissecting intramyocardial hematoma: clinical presentation, pathophysiology, outcomes and delineation by echocardiography. *Echocardiography*. 2009;26(3):254-61. DOI:10.1111/j.1540-8175.2008.00804.x.Epub 2008 Nov 1. PMID: 19017318.
 9. Leitman M, Tyomkin V, Sternik L, Copel L, Goitein O, Vered Z. Intramyocardial dissecting hematoma: Two case reports and a meta-analysis of the literature. *Echocardiography*. 2018;35(2):260-266. DOI: 10.1111/echo.13796. Epub 2018 Jan 9. PMID: 29315786.
 10. Zhao Y, He YH, Liu WX, Sun L, Han JC, Man TT, Gu XY, Chen Z, Wen ZY, Henein MY. Intramyocardial Dissecting Hematoma after Acute Myocardial Infarction-Echocardiographic Features and Clinical Outcome. *Echocardiography*. 2016;33(7):962-9. DOI: 10.1111/echo.13198. Epub 2016 Feb 19. PMID: 26895974.
 11. Lee TJ, Roslan A, Teh KC, Ghazi A. Intramyocardial dissecting haematoma mimicking left ventricular clot, a rare complication of myocardial infarction: A Case report. *Eur Heart J Case Rep*. 2019;3(2):ytz056. DOI:10.1093/ehjcr/ytz056

© 2022 Sen and Tanwar; This is an Open Access article distributed under the terms of the Creative Commons Attribution License (<http://creativecommons.org/licenses/by/4.0>), which permits unrestricted use, distribution, and reproduction in any medium, provided the original work is properly cited.

Peer-review history:

The peer review history for this paper can be accessed here:
<https://www.sdiarticle5.com/review-history/85777>